Bonnie S. Klapper, Esq.
[redacted]
bonniesklapper@bskesq.com
Tel: [redacted]
Admitted in NY, California and District of Columbia
Pro hac vice Florida and Texas

Bonnie S. Klapper, Esq.
On behalf of Coalition to Stop Thanksgiving Fraud and Abuse

November 23, 2026

Brandi L. Schiefelbein, Esq.
Meeker County Attorney
Meeker County Justice Center
325 North Sibley Avenue
Litchfield, Minnesota 55355
brandi.schiefelbein@co.meeker.mn.us

Brian Cruze
Sheriff, Meeker County
326 North Ramsey Avenue
Litchfield, Minnesota 55355
brian.cruze@co.meeker.mn.us

Keith Ellison
Attorney General, State of Minnesota
445 Minnesota Street, Suite 600
St. Paul, Minnesota 55101
attorney.general@ag.state.mn.us

Re: Violations of Minn. Stat. § 343.21 at the Jennie-O Turkey Store Grow-Out Farm, 68651 315th Street, Litchfield, Meeker County, Minnesota

Dear County Attorney Schiefelbein and Attorney General Ellison:

By this letter, and on behalf of the Coalition to Stop Thanksgiving Fraud and Abuse, I write to report ongoing, long-time and extensive violations of Minnesota's animal cruelty laws at Jennie-O Turkey Store ("Jennie-O"), located at 68651 315th Street, Litchfield, Meeker County, Minnesota. By way of background, I am an attorney licensed to practice in California, New York, and Washington, D.C., and admitted in several federal courts. From 1988 to 2012, I served as a federal prosecutor, first in the Central

District of California and then in the Eastern District of New York, where my duties included evaluating evidence and witness testimony to determine whether charges should be filed. About eighty percent of my current work is pro bono work for animal rights organizations, animal shelters, dog rescues around the world, and sanctuaries. As a result of my criminal law background and my work for these non-profits, I have made an extensive study of the laws governing animal cruelty in the United States. My criminal animal cruelty opinions and referrals contributed to the appointment of a special prosecutor in the case of Ridglan Farms, a commercial dog breeder in Wisconsin which experimented on dogs and was recently shut down.

After reviewing photographs and video taken inside a barn at the farm on October 9, 2026, the veterinary records of five turkeys removed from the farm that day, an opinion from an expert veterinarian, Jennie-O's own veterinary prescription records for the farm, historical data, and the relevant statutes and case law, I have concluded that the conditions at the farm violate Minn. Stat. § 343.21. Turkeys with large, infected wounds, swollen and deformed joints, and bloody diarrhea were left in the flock for days without isolation, treatment, or humane euthanasia, in crowded, soiled conditions that produce gangrenous dermatitis, a painful disease. There is probable cause to believe that Jennie-O, and those who direct its operations, are engaged in ongoing acts of criminal animal cruelty. I respectfully ask that your offices open an immediate investigation and, upon confirming these violations, prosecute.

This letter summarizes (A) the governing Minnesota statutes; (B) Jennie-O's documented history of animal abuse; (C) the evidence of current, ongoing cruelty gathered at the farm in October 2026; (D) why this conduct violates Section 343.21 and may be timely prosecuted; and (E) the action we request. The conditions at the farm, described below, caused severe and unnecessary suffering to the turkeys in Jennie-O's care.

A. Minnesota Law Broadly Prohibits Cruelty to Animals, Including Turkeys Raised for Food

Chapter 343 of the Minnesota Statutes governs criminal cruelty to animals. Under Minnesota law, the term "animal" is defined as "every living creature except members of the human race." See Minn. Stat. § 343.20, subd. 2. Thus, unlike in some states which differentiate between farmed animals and companion animals, in Minnesota, **all** animals are protected under the animal cruelty statute. Chapter 343 contains no exemption for animals raised for food or for customary farming practices. A turkey confined on a

commercial farm is protected to the same degree as any other animal.

Minnesota's animal cruelty statute states as follows:

> No person shall overdrive, overload, torture, cruelly beat, neglect, or unjustifiably injure, maim, mutilate, or kill any animal, or cruelly work any animal when it is unfit for labor, whether it belongs to that person or to another person.

Minnesota law punishes not just those who commit acts of criminal animal cruelty, but also those who instigate or further any act of cruelty:

> No person shall willfully instigate or in any way further any act of cruelty to any animal or animals, or any act tending to produce cruelty to animals.

See Minn. Stat. § 343.21, subds. 1, 7.

Two further provisions protect animals held in confinement:

> No person shall deprive any animal over which the person has charge or control of necessary food, water, or shelter.
>
> No person shall keep any cow or other animal in any enclosure without providing wholesome exercise and change of air.

See Minn. Stat. § 343.21, subds. 2, 3.

A violation of any of these provisions is a crime: "a person who fails to comply with any provision of this section is guilty of a misdemeanor." Minn. Stat. § 343.21, subd. 9(a). In Minnesota, a misdemeanor is punishable by up to 90 days in custody, a fine of up to $1,000, or both. See Minn. Stat. § 609.02, subd. 3.

In sum, Minnesota makes it a crime to neglect an animal, to deprive an animal in one's charge of necessary food, water, or shelter, to keep an animal in an enclosure without wholesome exercise and change of air, and to willfully further any act of cruelty or any act tending to produce it. These protections extend to every living creature other than a human being, including each of the thousands of turkeys confined at Jennie-O.

As set forth below, the evidence establishes probable cause to believe that those responsible for Jennie-O have violated these provisions.

B. <u>Jennie-O Has a Documented History of Animal Abuse</u>

The turkey industry is big business in Minnesota. The state consistently ranks first in turkey production, with an estimated 40 to 42 million turkeys raised and slaughtered a year.[1] There are approximately 600 turkey farms in Minnesota. Industry estimates place the value of the turkey industry in Minnesota at approximately $1 billion.

Jennie-O was founded in 1953 by Earl B. Olson. It was acquired by Hormel Foods, a massive food processing company, in 1986. Jennie-O Farms is now considered one of the largest turkey farms/processors in the country.[2] Jennie-O claims to raise its turkeys in an ethical fashion.[3]

Despite Jennie-O's pronouncements about how ethical and modern its facilities are, the reality is quite different.

In April 2021, People for the Ethical Treatment of Animals referred Jennie-O for investigation to federal authorities in Minnesota for violations of the Poultry Products Inspection Act after multiple United States Department of Agriculture/Food Safety and Inspection Service ("USDA/FSIS") inspections revealed that, in January 2020:

> 65 turkeys had sustained fractured wings and/or acute bruises – up to 11 inches long – on their legs at the slaughterhouse located at 2505 Willmar Avenue, SW, Willmar. Upon investigation, a federal agent saw a worker use so much force to unload live turkeys off a truck that the animals' legs struck a bar and the birds were sent onto a conveyor with so much momentum that they hit a wall.[4]

In February 2020, an FSIS agent saw several Jennie-O workers:

> Yanking . . . aggressively on up to 50 turkeys who had collected on a conveyor at the slaughterhouse located at 1116 Fourth Avenue, NW, Faribault. The federal

[1] https://www.minnesotaturkey.com/about/turkey-facts

[2] https://www.hormelfoods.com/about/our-family/jennie-o-turkey-store/#:~:text=Jennie%2DO%20Turkey%20Store%2C%20Inc,turkey%20products%20in%20the%20nation.

[3] https://www.jennieo.com/who_we_are/our-company/raising-a-healthy-turkey/

[4] https://www.peta.org/media/news-releases/feds-find-scores-of-birds-mutilated-at-jennie-o-slaughterhouses-peta-seeks-criminal-probe/

> inspector saw that the animals' legs were fractured, that their muscles and skin were torn and mutilated, and that the conveyor belt was covered with blood.[5]

In October 2021, the Animal Welfare Institute asked two county sheriffs in Minnesota to undertake a criminal animal cruelty investigation into Jennie-O and another turkey producer in Minnesota. The letter requesting the investigation noted that Jennie-O's establishment in Faribault ranked among the worst poultry slaughter plants in the country, having received dozens of reprimands from the USDA from 2018 to 2019 for malfunctioning stunning equipment that grossly mutilated turkeys.[6] Among other violations, at a Jennie-O in Melrose, hundreds of turkeys died from heat stroke after being left in brutal temperatures without fans or misters. Turkeys were observed being run over by trucks in unloading areas. Carbon dioxide stunners malfunctioned, leaving the birds to be drenched and shivering in freezing water.[7]

In 2023, this author, after reviewing footage from Jennie-O and a veterinary opinion, requested that Steele County law enforcement investigate Jennie-O. (Ex. A.) The footage obtained by investigators at that time showed that:

> Turkeys at the facility live in severely overcrowded conditions. Stress from lack of space is likely the primary cause of multiple serious wounds and lacerations seen on birds in the footage. Wounds go untreated, leading to infection and death. Non ambulatory animals suffer for days, unable to reach food or water before they ultimately die without veterinary care. Dead, decomposing animals are left for weeks among the living who peck at the carcasses. Infected carcasses spread disease among the living and risk foodborne illness in human consumers.

In March 2025, the Animal Legal Defense Fund filed an application to the Eighth Judicial District Court in Meeker County to obtain a search warrant and investigation into Jennie-O. The application stated that, in 2023, Jennie-O had violated Minnesota law by mass-killing over 50,000 turkeys using the process of ventilation shutdown.[8] Ventilation shutdown is one of the cruelest,

---

[5] https://www.peta.org/media/news-releases/feds-find-scores-of-birds-mutilated-at-jennie-o-slaughterhouses-peta-seeks-criminal-probe/

[6] https://awionline.org/press-releases/minnesota-law-enforcement-urged-investigate-butterfield-jennie-o-animal-cruelty

[7] https://awionline.org/sites/default/files/publication/digital_download/20TheWelfareBirdsSlaughter.pdf

[8] https://aldf.org/case/seeking-warrant-to-investigate-jennie-o-for-animal-cruelty-in-violation-of-the-law/

if not the cruelest, methods of mass-killing animals. Ventilation shutdown is executed by sealing up the building in which the animals are housed, closing all vents and fans, pumping carbon dioxide into the building and turning up the temperature in the building. The animals killed by ventilation shutdown are basically boiled alive. The World Health Organization prohibits the use of ventilation shutdown because of the massive amount of pain to which it subjects animals.

In May 2025, the FSIS documented an incident at the Jennie-O slaughterhouse in Willmar, Minnesota. An FSIS veterinarian inspecting the slaughterhouse found a turkey on the floor in front of the truck hoist, severely injured, with its liver visible and in agonal breathing. The turkey died while she was showing it to a supervisor. An investigation revealed that the turkey had been run over by a truck; Jennie-O's solution was to add a second visual inspection before trucks moved.

In May 2026, the FSIS documented a second incident at the Jennie-O slaughterhouse in Willmar, Minnesota. The report noted that on one day in May 2026, between 3.36% and 6.68% of the turkeys in each of three lots arrived at the slaughterhouse **already dead.** The incident report noted that misters meant to keep the turkeys cool in hot weather were not working. The turkeys died of heat stroke.[9]

None of these documented acts of criminal animal cruelty resulted in any investigation, let alone a prosecution.[10]

---

[9] U.S. Dep't of Agric., Food Safety & Inspection Serv., Poultry Good Commercial Practices Inspection Task Data, Memoranda of Interview Nos. WJL5912051209G (May 9, 2025) and WJL2612063102G (June 2, 2026), Jennie-O Turkey Store, Willmar, MN (Est. P551) (FY2025 Q3 and FY2026 Q3 data files), https://www.fsis.usda.gov/science-data/data-sets-visualizations/inspection-task-data

[10] Jennie-O also has a documented history of mistreatment of its own workers. In 2012, the Occupational Safety and Health Administration ("OSHA") cited Jennie-O for eleven safety violations at its plant in Barron, Wisconsin after an employee had his arm severed and had to walk down a flight of steps and across the production floor to get help. In 2014, OSHA opened an investigation into a Jennie-O facility in Willmar, Minnesota, when 28 employees on the production floor fell sick from a flu-like illness. In 2016 and 2017, OSHA again cited a Jennie-O facility for serious safety violations. In 2020, OSHA found a serious safety violation at the turkey plant in Faribault. In 2016, the Department of Labor ordered Jennie-O to pay $492,000 in back wages to 339 female applicants after the Department found that Jennie-O had engaged in hiring discrimination.

C. There Is Current, Ongoing Criminal Animal Cruelty at Jennie-O

1. Turkeys at Jennie-O Were Left to Suffer Painful, Untreated Diseases

As noted above, Jennie-O is a commercial turkey grow-out farm. A grow-out facility is a specialized agricultural housing structure where young turkeys are raised until they reach market weight and are ready for slaughter. The evidence described below concerns the care of the turkeys confined at Jennie-O, and in particular, the failure to identify, isolate, treat, or humanely euthanize birds suffering from painful and plainly visible disease.

The evidence I reviewed was gathered on October 9, 2026, when investigators documented the conditions inside a barn at Jennie-O with photographs and video. (Ex. B.) The photographs show thousands of young turkeys filling the barn floor. (Ex. B, photograph 1.) The investigators removed five turkeys from the barn and took them for veterinary care. Each of the five was a juvenile Broad Breasted White turkey, approximately four months old, marked with a colored leg tie (yellow, orange, blue, green, or red), by which each is identified below. All five were examined the same day by veterinarians and re-examined over the following two weeks. (Ex. C.) Dr. Sherstin Rosenberg, a veterinarian who has examined and treated thousands of commercial turkeys, reviewed these veterinary records and the photographs and video, and observed all five turkeys by video on the day of their removal. Her opinion is attached as Exhibit A.

Every one of the five turkeys required immediate veterinary care. All five were dehydrated; four had scabbed or open skin wounds; three had swollen joints; and blood-tinged diarrhea was found in most of the crates holding them. The examining veterinarian prescribed antibiotics, pain medication, and a wound antiseptic, and gave a guarded prognosis. (Ex. A; Ex. C.)

2. Turkeys With Large, Infected Wounds at Least Several Days Old Were Left in the Flock Without Care

The most serious injuries were large necrotic skin wounds. The yellow-tagged turkey had two large scabbed wounds covering most of both sides of its trunk. When the yellow-tagged turkey was re-examined five days later, the veterinarian found the wound on its left side to be “severe w/ major anterior/cranial pocketing down lateral aspect of the leg,” diagnosed infected wounds, and recorded that the bird needed surgery. (Ex. A; Ex. C.) Dr. Rosenberg explains that a wound that tracks beneath the skin down the leg is a deep, established infection; when she observed this bird on the day of its removal, its lesions were the most severe she has seen

on any turkey. (Ex. A.) The red-tagged turkey had a large scab covering most of the left side of its trunk, and on re-examination had scabbed wounds on both sides of its body, which the veterinarian diagnosed as infected. (Ex. A; Ex. C.) The green-tagged turkey had a wing wound that exposed the underlying muscle. (Ex. A; Ex. C.) Even the orange-tagged turkey, the least affected of the five, had three scabbed wounds. (Ex. A; Ex. C.)

These were not birds who happened to be injured the day the investigators arrived. The wounds were scabbed, encrusted, or pocketed; as Dr. Rosenberg explains, wounds in that advanced a state have been present for at least several days. (Ex. A.) Several days is a floor, not an estimate: the wounds may have been present considerably longer; the swollen joints and limb deformities found in the same birds take days to weeks to develop. (Ex. A.) Nor were these five birds isolated cases. Photographs taken inside the barn show other turkeys still in the flock with the same dark, necrotic lesions on their flanks and wings. (Ex. B, photographs 3–4.) Dr. Rosenberg concluded that the appearance, distribution, and prevalence of the wounds support a presumptive diagnosis of gangrenous dermatitis, a painful bacterial infection of the skin and underlying tissue of commercial poultry, whose incidence increases when sick and dead birds are not removed from the flock. (Ex. A.)

Dr. Rosenberg opined as follows:

> A lesion that can be photographed across a barn floor **can be seen by any caretaker who walks that floor**. The wounds in these birds were scabbed, encrusted, or pocketed, which means that they had been present for at least several days. . . . Under the daily observation that the standard of care requires, **each of these birds would have been identified and removed for treatment or humane euthanasia many times over before October 9**. Instead, these birds were still in the general flock on October 9.

(Ex. A, emphasis added.)

Leaving turkeys with large, infected, and plainly visible wounds in the flock for at least several days without treatment or humane euthanasia clearly violates Minnesota’s animal cruelty laws and warrants criminal investigation.

3. Lame Turkeys With Swollen and Deformed Joints Were Left in Pain, Competing for Food and Water

All five rescued turkeys had some degree of musculoskeletal disease. (Ex. A.) The green-tagged turkey’s left hock joint was

swollen and warm to the touch; on re-examination, fluid was drawn from a swelling of the left leg, and the bird was lame on that leg. (Ex. A; Ex. C.) The red-tagged turkey's left hock was severely swollen, its left leg was edematous with a grape-sized, fluid-filled swelling, and it was lame on that leg. (Ex. A; Ex. C.) The yellow-tagged turkey was bow-legged in both legs, which the veterinarian diagnosed on re-examination as a bilateral limb deformity. (Ex. C.) The blue-tagged turkey was underweight, with a swollen joint that crepitated (made a crackling noise) when manipulated; a veterinarian later found the joint "quite swollen, painful, and deviated at an abnormal angle," diagnosed a slipped tendon, discharged the bird on two pain medications with long-term pain management anticipated, and gave a poor prognosis for normal mobility. (Ex. C.) The examining veterinarian was concerned that the swollen joints were septic, which Dr. Rosenberg explains is a known consequence of extensive skin infection seeding bacteria into the bloodstream. (Ex. A; Ex. C.)

Dr. Rosenberg observed these injuries herself. On the day of the birds' removal, she watched all five by video as a caretaker positioned and moved each bird. The green-tagged turkey sat on its hocks with its feet extended forward, an abnormal posture most likely caused by leg pain, and its left leg below the hock was roughly twice the diameter of the right. The red-tagged turkey's left leg was similarly enlarged, and it limped severely when it tried to walk. The blue-tagged turkey stood hunched, and the orange- and green-tagged turkeys stood only with difficulty. Two of the birds were heavily soiled with feces, which Dr. Rosenberg explains is typical of lame birds that spend most of their time lying in soiled litter in crowded conditions. (Ex. A.) A photograph taken inside the barn shows a bird still in the flock standing with an abnormal, splayed-leg posture. (Ex. B, photograph 5.) In Dr. Rosenberg's opinion, most or all of the five birds were unlikely to survive without extensive veterinary treatment, and a few may need lifelong assistance to move. (Ex. A.)

Dr. Rosenberg opined as follows:

> Full-thickness skin loss, deep infected wounds, and inflamed, distended joints **are painful conditions**; every treating veterinarian prescribed pain medication . . . . A lame turkey in a crowded barn must compete with thousands of heavier, mobile birds to reach feeders and drinkers, and **lameness alone is a significant source of suffering** in a bird of this body weight.

(Ex. A, emphasis added.)

Leaving lame turkeys with painful, swollen, and deformed

joints in a crowded barn, where they must compete with thousands of other birds for food and water, clearly violates Minnesota's animal cruelty laws and warrants criminal investigation.

4. Dehydration, Bloody Diarrhea, Intestinal Disease and Gangrenous Dermatitis

All five turkeys were approximately 5% dehydrated when examined on the day of their removal, and blood-tinged diarrhea was found in most of the crates holding them. The examining veterinarian suspected coccidiosis, a parasitic intestinal disease. (Ex. A; Ex. C.) Afterward, the birds' caretakers reported that small worms were thought to have been seen in a few fecal samples. (Ex. C.) Dr. Rosenberg found that a photograph of feces from one of the rescued turkeys reveals the presence of roundworms. (Ex. A.) Dr. Rosenberg explains that coccidiosis spreads through contaminated litter, and that its presence in birds drawn from the flock suggests that the flock as a whole was exposed. (Ex. A.) Bloody diarrhea adds intestinal disease to the pain of the birds' wounds and joints. (Ex. A.)

Dr. Rosenberg also diagnosed the five turkeys with a condition called gangrenous dermatitis:

> Birds had large necrotic skin wounds consistent with gangrenous dermatitis, swollen joints, and leg deformities, all of which are painful.

(Ex. A.)

The National Institutes of Health define gangrenous dermatitis as "a fast-moving, often fatal bacterial skin and tissue disease . . . ."

The photographs taken by investigators show a barn floor filled with turkeys, birds crowded together at bird level, and birds with broken, soiled plumage. (Ex. B, photographs 1, 2, 4.) These are the very conditions that cause gangrenous dermatitis. The Merck Veterinary Manual explains that preventing the disease includes avoiding skin trauma related to overcrowding, and that failing to remove sick and dead birds increases its incidence. (Ex. A.) As Dr. Rosenberg explains, gangrenous dermatitis "is a disease of management: crowding, wet and soiled litter, and the retention of sick and dead birds in the flock are the conditions that produce it, and it is controlled by correcting those conditions." (Ex. A.) Gangrenous dermatitis is not new to Jennie-O; Jennie-O's own records show skin disease diagnosed in flocks of nearly the same age in the autumns of 2021 and 2022. (Ex. D.)

The suffering these many health conditions produced was also relievable. Dr. Rosenberg explains that wounded and lame turkeys should be moved to a hospital pen with easy access to food and water and given wound care, antibiotics, and pain relief, or humanely euthanized if their condition cannot be relieved. (Ex. A.) The five birds removed from the farm responded to exactly that care: twelve days after their rescue, the treating veterinarian recorded that the orange- and blue-tagged turkeys had improved significantly, with good appetite and activity. (Ex. A; Ex. C.) Keeping thousands of turkeys in crowded, soiled conditions that produce a painful and preventable disease, and failing to correct those conditions or to care for the birds they harmed, clearly violates Minnesota's animal cruelty laws and warrants criminal investigation.

Dr. Rosenberg opined as follows:

> **A disease that returns on schedule is a management failure.** Its recurrence indicates that the conditions that cause it—namely crowding, soiled litter, skin trauma, and the retention of sick and dead birds—were not corrected.

(Ex. A, emphasis added.)

Jennie-O's repeated diagnosis of the same painful disease at this farm establishes that it knew of the disease and of the conditions that produce it, and it failed utterly to correct those conditions, which further supports a criminal investigation.

D. The Evidence Establishes Probable Cause That Section 343.21 Has Been Violated

As set forth above, Minnesota's criminal animal cruelty laws make it a crime to, in relevant part, overdrive, overload, torture, cruelly beat, neglect, or unjustifiably injure, maim, mutilate, or kill any animal. A person can be guilty of criminal animal cruelty if he or she instigates or in any way furthers any act of cruelty. See Minn. Stat. § 343.21, subds. 1, 7. Each element of the animal cruelty statute is met by the conduct documented at Jennie-O.

Neglect (subdivision 1). The turkeys are "animals" under the statute. Minn. Stat. § 343.20, subd. 2. They suffered painful wounds and joint disease, for which every treating veterinarian prescribed pain medication. (Ex. A; Ex. C.) That pain was caused by severe, intentional neglect: birds with infected wounds at least several days old, and with swollen and deformed joints, were left in the flock rather than isolated, treated, or humanely euthanized. (Ex. A; Ex. B, photographs 3–5.) And it was unnecessary and unjustifiable, because these conditions are preventable through

standard flock management and relievable through basic veterinary care or humane euthanasia. (Ex. A.)

Willfully furthering cruelty (subdivision 7). Subdivision 7 reaches anyone who "in any way further[s] any act of cruelty" or "any act tending to produce cruelty," including through decisions about how animals are kept. Minn. Stat. § 343.21, subd. 7. The birds' suffering was obvious, and that turkeys suffered from skin conditions was known; Jennie-O's own veterinarian prescribed skin medication at this farm in consecutive years, and Jennie-O says its staff visit its farms weekly. (Ex. A; Ex. D; see Section C, above.) Yet the conditions that produce the disease continued, and sick birds were left without care. Continuing to keep thousands of turkeys in conditions known to produce a painful disease, while birds visibly suffering from it go untreated, is willfully furthering cruelty. The Minnesota Supreme Court has long held that responsibility for confined animals rests on their owner, and that an owner who is warned of their condition and fails to investigate or act is criminally liable for the resulting suffering. See *State v. Klammer*, 230 Minn. 272, 41 N.W.2d 451 (1950).

Confinement and deprivation (subdivisions 3 and 2). The photographs show turkeys crowded across the barn floor on soiled litter, conditions Dr. Rosenberg ties directly to gangrenous dermatitis. (Ex. A; Ex. B, photographs 1–2.) That evidence supports a violation of subdivision 3, which requires that animals kept in an enclosure be provided "wholesome exercise and change of air." And because all five rescued birds were dehydrated, and lame birds must compete with thousands of others for feed and water, an investigation likely will reveal violations of subdivision 2, which prohibits depriving animals of "necessary food, water, or shelter." (Ex. A; Ex. C.)

Who is responsible. A corporation may be prosecuted for animal cruelty like any other person where its management authorized, tolerated, or ratified the conduct. See Minn. Stat. § 645.44, subd. 7; *State v. Christy Pontiac-GMC, Inc.*, 354 N.W.2d 17 (Minn. 1984). The conduct here reflects Jennie-O's own practices, not one employee's lapse: its veterinarian diagnosed skin disease at this farm year after year. Yet Jennie-O did nothing to correct the conditions, and the same failures were documented at a different Jennie-O facility in 2023. (Ex. A; Ex. D.) The individual managers, caretakers, and supervisors responsible for these birds are also liable, directly or for aiding the offenses. Minn. Stat. § 609.05.

No agricultural exemption. Chapter 343 does not contain any exemption for animals raised for food or for customary farming practices. To the contrary, the Legislature specifically provided a procedure for seizing "an animal raised for food or fiber products"

in cruelty cases. Minn. Stat. § 343.235, subd. 1. Nor is industry practice a defense. Leaving birds with days-old, infected wounds untreated in the flock departs from the basic standard of care, daily observation and the prompt removal of sick and injured birds, that is reflected in Jennie-O's own public commitments. (Ex. A.)

Timeliness. A misdemeanor violation of Section 343.21 may be prosecuted within three years. Minn. Stat. § 628.26. The October 2026 conduct is well within that period. The evidence is also fresh. In March 2025, the Meeker County District Court denied an application to investigate an October 2023 incident at this same farm, in part because the evidence was then 17 months old. (Ex. E.) The evidence here is weeks old, and because the disease recurs with each flock, an investigation now is likely to find the same conditions.

E. Conclusion and Requested Action

The enclosed evidence establishes probable cause to believe that turkeys at the Litchfield farm are being subjected to ongoing criminal neglect and cruelty in Meeker County. We respectfully request that:

- The Meeker County Attorney open a criminal investigation into violations of Minn. Stat. § 343.21 by Jennie-O, any other operator of the farm, and the individuals who direct its operations, and prosecute those responsible where violations are confirmed;
- The Meeker County Attorney coordinate with law enforcement and humane agents to seek a warrant under Minn. Stat. § 343.22 for a prompt, unannounced inspection of the farm with a licensed veterinarian, and to remove and care for animals as warranted under Minn. Stat. §§ 343.22 and 343.235; and
- The Attorney General assist the County Attorney with investigative and prosecutorial resources pursuant to Minn. Stat. § 8.01.

Dr. Rosenberg is available to consult with your offices, and the complete photographs and veterinary records are available upon request.

Thank you for your attention to this urgent matter. A new flock is placed at this farm with each cycle. Every flock raised under these conditions means that thousands more turkeys are left to suffer and die without care.

Respectfully submitted,

Bonnie S. Klapper, Esq. on behalf of
Coalition to Stop Thanksgiving
Fraud and Abuse

Enclosures:

- Exhibit A – Veterinary Expert Report of Sherstin L. Rosenberg, D.V.M.
- Exhibit B – Photographs from Inside the Litchfield Farm, October 9, 2026
- Exhibit C – Veterinary Records of the Five Turkeys Removed from the Farm (Redacted), October 9–21, 2026
- Exhibit D – Jennie-O Turkey Store Veterinary Drug Prescriptions for the Litchfield Farm, 2021–2022
- Exhibit E – Order Denying Search Warrant Application, Meeker County District Court File No. 47-CV-25-274 (Mar. 28, 2025)

EXHIBIT A

Veterinary Expert Report of Sherstin L. Rosenberg, D.V.M. (Nov. 16, 2026)

SHERSTIN L. ROSENBERG, D.V.M.
Happy Hen Animal Sanctuary
[redacted]
[redacted] · sherstin@happyhen.org
California Veterinary License No. 13432

November 16, 2026

VETERINARY EXPERT REPORT
Jennie-O Turkey Store / Hormel Foods Corporation
Turkey grow-out facility at 68651 315th Street, Litchfield, Meeker County, Minnesota

I. Assignment and Summary of Opinions

Counsel has asked me whether the evidence from a Jennie-O Turkey Store ("Jennie-O") turkey farm at 68651 315th Street, Litchfield, Meeker County, Minnesota, establishes the veterinary facts relevant to Minnesota's animal cruelty statute, which defines cruelty as any "act, omission, or neglect which causes or permits unnecessary or unjustifiable pain, suffering, or death" (Minn. Stat. § 343.20, subd. 3).

In my opinion, held to a high degree of veterinary certainty, turkeys at this farm suffered unnecessary and unjustifiable pain through neglect:

- **Pain and suffering:** Birds had large necrotic skin wounds consistent with gangrenous dermatitis, swollen joints, and leg deformities, all of which are painful.
- **Neglect:** The wounds were several days old and visible on routine inspection, yet affected birds remained in the general flock rather than being isolated, appropriately treated, or humanely euthanized.
- **Unnecessary and unjustifiable:** These conditions are frequently preventable through standard flock management and, once present, relievable through basic veterinary care or humane euthanasia.

These opinions rest on the veterinary records of five turkeys removed from the farm on October 9, 2026, each of whom required immediate veterinary care; photographs and video of birds still in the barn with the same lesions; and Jennie-O prescriptions prescribing medication for whole flocks at this farm for dermatitis and *E. coli* in 2021 and 2022. Prior complaints concerning Jennie-O, including the October 2023 ventilation-shutdown killings at this same farm, are summarized in Part IV.

II. Qualifications

I have been a licensed veterinarian in California for more than 25 years. I graduated from the University of California, Davis, School of Veterinary Medicine- consistently ranked the leading veterinary school in the United States- in 1998, after undergraduate study at Stanford University.

Since 2014 I have been Executive Director and Chief Veterinarian of Happy Hen Animal Sanctuary, where I have examined, treated, and cared for thousands of commercial turkeys, chickens, and other poultry, a large proportion of them removed from commercial production facilities. The conditions described in this report, including gangrenous dermatitis, septic and deformed joints, and parasitic and coccidial disease, are conditions I diagnose and treat in commercial-strain turkeys as a routine part of my practice. I have also served on the Board of Directors, and as Chair of the Ethics Committee, of a large humane society in Santa Clara County, California.

I have been retained as an expert in numerous criminal and civil matters involving animal welfare and industry husbandry standards, and have testified in legislative and administrative hearings. In 2023 I gave a veterinary opinion concerning a different Jennie-O turkey facility in Steele County, Minnesota, which was submitted to law enforcement with a criminal referral.

III. Materials Reviewed

- Veterinary records for the five turkeys removed from the facility, each examined on October 9, 2026, and identified by a colored leg tie, including intake photographs (the Turkey 3 record is available here);
- Follow-up examination records for the yellow turkey (October 14, 2026), the red turkey (October 14, 2026), and the green turkey (October 15, 2026);
- Discharge reports for the blue turkey (October 21, 2026) and the orange turkey (October 21, 2026);
- Photographs and video recorded inside the barn, including a view of the barn and flock, crowding at bird level, birds in the flock with necrotic lesions (1, 2, 3), birds with abnormal posture and gait (1, 2), and video clips of soiled, featherless birds on the litter and the barn interior;
- Photographs of wounds taken at veterinary intake (1, 2);
- Four Jennie-O Turkey Store Veterinary Drug Prescriptions for this farm, photographed at the facility on October 9, 2026, dated September 8, 2021, November 9, 2021, August 9, 2022, and October 10, 2022;
- The March 20, 2025 application of the Animal Legal Defense Fund and Animal Partisan to the Meeker County District Court for a search warrant concerning this facility (case summary), and the court's March 28, 2025 order on that application;

- My own contemporaneous notes of a remote video observation of all five turkeys on October 9, 2026, the day of their removal;
- My written assessment, Reasons for Presumptive Diagnosis of Gangrenous Dermatitis in 5 Rescued White Broad Breasted Turkeys; and
- The published standards identified in Part V.

The prescriptions identify the farm by name and by its address at 68651 315th Street, Litchfield, Minnesota 55355, and record Jennie-O's Hawick warehouse as the dispensing location. The five turkeys were juvenile Broad Breasted White turkeys approximately 4 months old.

IV. Background: Prior Complaints Concerning Jennie-O

Two prior complaints concern Jennie-O's treatment of turkeys in Minnesota.

- **2023 criminal referral (Steele County).** In November 2023, a criminal referral supported by my veterinary opinion documented infected wounds without appropriate care, birds unable to walk, dead birds left among the living, and intestinal parasites at a Jennie-O turkey facility in Steele County (referral and opinion).
- **2025 search-warrant application (this farm).** In March 2025, the Animal Legal Defense Fund and Animal Partisan asked the Meeker County District Court to order an investigation of Jennie-O's October 2023 killing of more than 50,000 turkeys at this farm by "ventilation shutdown plus": the barns were sealed and heated to 104°F, and the birds died over approximately three to four hours (ALDF announcement). The court's order confirms the farm's address (order, Finding 4). The court denied the warrant application, citing the age of the evidence and the agencies' authorization of the depopulation; it did not examine the method's effect on the birds. In my opinion, killing conscious birds by heatstroke over several hours causes severe and prolonged suffering.

The failures documented in this report, at a different facility from the 2023 referral and three years later, closely match those I documented in 2023. Together with the findings in this report, these complaints show a repeated pattern of serious violations of accepted animal welfare standards in Jennie-O's Minnesota turkey operations.

V. The Applicable Standards

Minnesota law. I understand that Minnesota law defines animal cruelty as any act, omission, or neglect that causes or permits unnecessary or unjustifiable pain, suffering, or death (Minn. Stat. § 343.20, subd. 3). My opinions address the veterinary facts relevant to that definition: whether the turkeys experienced pain and suffering, whether that suffering resulted from neglect, and whether proper care would have prevented or relieved it.

The veterinary standard of care for commercial turkeys. Any person responsible for a flock must observe the birds at least daily, identify birds that are injured, lame, or ill, and promptly remove them for treatment or humane euthanasia. This is basic flock management and is reflected in the industry's own commitments: the National Turkey Federation states that turkeys are raised with room to move about in protective barns, and that veterinarians prescribe medications. Jennie-O itself represents that it is "the advocate for the animals," that it employs veterinarians, nutritionists, and flock supervisors, and that its staff visit its farms weekly.

Gangrenous dermatitis. Gangrenous dermatitis is a bacterial infection of the skin and underlying tissue of commercial turkeys and broiler chickens, caused chiefly by *Clostridium* species, with lesions most often on the breast, abdomen, back, thighs, legs, and wings. The Merck Veterinary Manual identifies fever, listlessness, anorexia, ataxia, and recumbency as its main clinical signs, explains that failing to remove moribund or dead birds increases its incidence, and states that prevention includes avoiding skin trauma related to overcrowding. It is a disease of management: crowding, wet and soiled litter, and the retention of sick and dead birds in the flock are the conditions that produce it, and it is controlled by correcting those conditions.

Drugs in food-producing animals. A veterinarian may use a drug in a food animal other than as labeled only within narrow federal conditions, including a substantially extended withdrawal period "supported by appropriate scientific information" (21 C.F.R. § 530.20(a)(2)(ii)). A drug approved only for animals not intended for human consumption may be used in food animals only with an appropriate medical rationale, and where scientific information on its food safety in food animals is not available, the veterinarian "must take appropriate measures to assure that the animal and its food products will not enter the human food supply" (§ 530.20(b); FDA guidance). Accepted principles of judicious antimicrobial use require that "management and prevention strategies should be employed to minimize the need for antimicrobial drugs" and that therapy be targeted "to ill or at-risk animals when possible" (AVMA). The FDA ranks trimethoprim-sulfonamide combinations as "critically important" to human medicine, and penicillins and tetracyclines as "highly important" (FDA Guidance for Industry #152, Appendix A).

VI. Opinion 1: The Turkeys Suffered Severe, Painful Infections and Injuries Without Appropriate Care

Condition on removal. On examination the day of their removal, all five turkeys were approximately 5% dehydrated (intake record), and blood-tinged diarrhea (hematochezia) was present in the majority of the crates holding them. Four of the five had scabbed or open skin wounds; three had swollen joints. The examining veterinarian recorded concern for septic joints and for coccidiosis, prescribed antibiotics, an anti-inflammatory pain medication, and an antiseptic for the wounds, and gave a guarded prognosis.

Turkey 1 (yellow). At intake this turkey had two large scabbed wounds covering most of her left and right trunk, was bow-legged, and had bloody diarrhea. On re-examination five days later, the veterinarian found the left-sided wound "severe w/ major anterior/cranial pocketing down lateral aspect of the leg," diagnosed infected wounds and a bilateral varus deformity of the legs, and recorded that the bird needed surgical intervention for the pocketing (October 14 record). A wound that tracks beneath the skin down the leg is a deep, established infection. When I observed this bird by video on the day of its removal, her lesions were the most severe I have seen on any turkey.

Turkey 5 (red). At intake this turkey had a large scab covering most of the left trunk and a severely swollen left hock joint. At follow-up, the veterinarian recorded "bilateral scabbed wounds on the body with the left sided wound being larger and more severe than the right"; the left leg was edematous with a grape-sized fluid-filled swelling, the bird was lame on that leg, and the veterinarian diagnosed infected skin wounds (October 14 record).

Turkey 4 (green). This turkey had a wing wound with an opening that exposed underlying muscle, and a left hock joint that was moderately swollen and warm to the touch. At follow-up, fluid was aspirated from a fluctuant swelling of the left leg, and the bird was lame on that leg (October 15 record).

Turkey 3 (blue). This turkey was underweight (body condition score 2 of 5), with a swollen right hock joint that crepitated on manipulation, bruising, and an irregular heart rhythm (intake record). A veterinarian later found the joint "quite swollen, painful, and deviated at an abnormal angle," diagnosed a slipped tendon, discharged the bird on two pain medications with long-term pain management anticipated, and gave a poor prognosis for normal mobility, noting that the condition is common in poultry that grow at excessive rates or have nutritional imbalances (October 21 report).

Turkey 2 (orange). The least affected bird still had three scabbed wounds, bruising, broken feathers, fecal staining, and bloody diarrhea, and at recheck had mild joint swelling and diffuse feather breakage (October 21 report).

Diagnosis. The skin lesions I reviewed were brown to black, encrusted, and necrotic; they were located on the trunk and wings and in several birds covered areas eight inches or more across, in addition to extensive bruising and feather loss over the wings, trunk, and legs (intake photographs; close view). Their appearance, distribution, and prevalence match gangrenous dermatitis as I have diagnosed it in other commercial turkeys and support a presumptive diagnosis of that disease. Trauma may have contributed to some lesions, and one bird's full-thickness wing tear is most likely traumatic, but the extent and prevalence of the lesions point to an infectious cause (my assessment). Extensive skin infection of this kind can seed bacteria into the bloodstream and from there into joints, and the examining veterinarian was concerned that the swollen joints found in three of the five birds were septic. Later imaging of one of those birds attributed its joint deformity to a slipped tendon rather than infection. Musculoskeletal disease was present to some degree in all five.

My video observations. On October 9, 2026, I observed all five turkeys by video as a caretaker positioned and moved each bird. Turkey 4 sat on her hocks with her feet extended forward, an abnormal posture most likely caused by leg pain; her left leg below the hock was roughly twice the diameter of the right, and her wing tear exposed underlying muscle. Turkey 5's left leg was similarly enlarged, and she limped severely when she tried to walk. Turkey 3 stood hunched, and Turkeys 2 and 4 stood only with difficulty. Turkeys 3 and 4 were heavily soiled with feces, a finding typical of lame birds that spend most of their time lying in soiled litter in crowded conditions. Based on these observations, in my opinion most or all of these birds were unlikely to survive without extensive veterinary treatment, and some may need lifelong assistance to move.

Pain and suffering. Full-thickness skin loss, deep infected wounds, and inflamed, distended joints are painful conditions; every treating veterinarian prescribed pain medication, and one bird was discharged on two analgesics with long-term pain management anticipated. A lame turkey in a crowded barn must compete with thousands of heavier, mobile birds to reach feeders and drinkers, and lameness alone is a significant source of suffering in a bird of this body weight. Bloody diarrhea, for which the examining veterinarian suspected coccidiosis, adds intestinal disease to that pain.

Parasitic and coccidial disease. Bloody diarrhea was present at intake, and the birds' caretakers later reported that small worms were thought to be seen in a few fecal samples, prompting fecal testing (October 14 record). A photograph of feces from one of the rescued turkeys reveals the presence of roundworms. In addition, coccidia is an intestinal parasite that can cause bloody diarrhea, severe enteritis, and life-threatening secondary intestinal infections. The presumptive diagnosis of coccidia in the 5 turkeys strongly suggests flock-wide infection since coccidiosis spreads easily when litter and bedding are contaminated with infected feces.

VII. Opinion 2: The Conditions Were Present in the Flock and Were Left Without Appropriate Care

Prevalence. Four of five birds removed from the flock had skin wounds and all five had musculoskeletal disease. The photographs and video taken inside the barn show birds still in the flock with the same dark, necrotic lesions on the flank and wing (2, 3), birds with broken and soiled plumage, and a bird standing with an abnormal splayed-leg posture (image). Investigators reported that other turkeys at the farm were similarly affected (my assessment). The same barn holds thousands of birds filling the barn floor (image; image).

Visibility and duration. A lesion that can be photographed across a barn floor can be seen by any caretaker who walks that floor. The wounds in these birds were scabbed, encrusted, or pocketed, which means that they had been present for at least several days. Swollen joints with fluid accumulation and established limb deformities likewise take days to weeks to develop. Under the daily observation that the standard of care requires, each of these birds would have been identified and removed for treatment

or humane euthanasia many times over before October 9. Instead, these birds were still in the general flock on October 9.

What proper care would have provided. Wounded and lame turkeys should be moved to a hospital pen with easy access to food and water, given wound care, antibiotics, and pain relief, or humanely euthanized if their condition cannot be relieved. The response of these birds to basic care confirms that their suffering was relievable: twelve days after treatment began, the treating veterinarian recorded that the orange and blue turkeys had improved significantly since rescue, with good appetite and activity. The condition of these birds at removal is not consistent with that care having been provided.

VIII. Opinion 3: The Disease Was Known and Recurring, and Was Met With Mass Medication Rather Than Correction

The prescription records. The four Jennie-O prescriptions photographed at the facility show the following treatments, each prescribed for delivery through the drinking water of the entire flock:

- September 8, 2021: oxytetracycline, diagnosis "ECOLI," 10,366 birds at a recorded age of 7 (presumably 7 weeks), for 5 days;
- November 9, 2021: penicillin G, diagnosis "DERM," 9,376 birds at a recorded age of 16 (presumably 16 weeks), for 14 days;
- August 9, 2022: Equisul-SDT (sulfadiazine and trimethoprim), diagnosis "ECOLI," 9,479 birds at a recorded age of 8 (presumably 8 weeks), for 5 days, with a 45-day withdrawal period; and
- October 10, 2022: penicillin G, diagnosis "DERM," 8,855 birds at a recorded age of 17 (presumably 17 weeks), for 14 days.

A recurring outbreak. "DERM" is a standard veterinary abbreviation for skin, and penicillin in the drinking water is a flock-level treatment consistent with clostridial (gangrenous) dermatitis. The records therefore show a recurring skin disease diagnosis in flocks of nearly the same age (16 and 17 weeks), in the autumn of consecutive years, at the same farm, and the birds removed in October 2026, at a similar age, show lesions consistent with gangrenous dermatitis again. A disease that returns on schedule is a management failure. Its recurrence indicates that the conditions that cause it- namely crowding, soiled litter, skin trauma, and the retention of sick and dead birds- were not corrected. The documented response was flock-wide water medication of roughly 9,000 to 10,000 birds at a time with medically important antibiotics, while in 2026 individual birds with visible, painful lesions remained in the flock. Repeatedly medicating entire flocks for the same predictable diseases, rather than correcting their management causes, is contrary to accepted principles of judicious antimicrobial use (AVMA). The pattern is industry-wide: U.S. turkey producers report that their use of the antibiotic lincomycin has risen "due to increases in gangrenous dermatitis incidence" (USPOULTRY).

Jennie-O's stated commitments. Hormel says it focuses on "keeping our animals healthy so that antibiotics aren't needed," promises "identification of prompt treatment of sick animals," and claims

"a zero-tolerance policy toward the mistreatment of animals through abuse or neglect." Jennie-O has also agreed that medically important antibiotics "must be carefully managed to slow the emergence of resistant bacteria." Hormel's 2024 antibiotic stewardship report presents Jennie-O's manager of technical service and animal welfare as upholding the company's welfare commitments. That veterinarian approved all four prescriptions above, including the critically important to human health Trimethoprim Sulfa (Equisul-SDT). The evidence contradicts each of these commitments.

A pattern across Jennie-O facilities. The failures documented here, namely infected wounds without appropriate care, lameness, and parasitic disease, are the same ones I documented at Jennie-O's Steele County facility in 2023 (Part IV). Their recurrence at a different facility three years later indicates a systemic failure of the company's flock health and welfare program, not an isolated lapse by one caretaker.

IX. Conclusion

Turkeys at the Litchfield facility were kept in crowded conditions on soiled litter in which a painful, preventable, and recurrent skin infection spread through the flock. Birds with large necrotic wounds, swollen and deformed joints, and bloody diarrhea remained in the general flock with lesions several days old rather than being isolated, treated, or humanely euthanized. Jennie-O's own prescription records show recurring dermatitis and *E. coli* diagnoses at this farm in 2021 and 2022, addressed by flock-wide medication with medically important antibiotics, contrary to the company's own stated commitments, including a horse-only product (Equisul-SDT). The 2026 evidence shows that the conditions producing the disease persisted and that individual affected birds did not receive appropriate care.

In my professional opinion, held to a high degree of veterinary certainty, the turkeys at this farm experienced substantial pain and suffering; that suffering was permitted by the failure to identify, isolate, treat, or humanely euthanize affected birds; and it was unnecessary and unjustifiable, because the underlying conditions are preventable through standard management and relievable through basic veterinary care. I am prepared to explain these opinions under oath.

I will supplement these opinions if the facility's mortality, culling, treatment, or flock health records become available.

Respectfully submitted,



Sherstin L. Rosenberg, D.V.M.
Executive Director and Chief Veterinarian
Happy Hen Animal Sanctuary

EXHIBIT B

Photographs from Inside the Litchfield Farm, October 9, 2026

Exhibit B, Photograph 1



Interior of the barn, showing the flock filling the floor.

Exhibit B, Photograph 2



Turkeys crowded together, photographed at bird level.

Exhibit B, Photograph 3



Turkey in the flock with a dark lesion on its back.

Exhibit B, Photograph 4



Turkey in the flock with broken, soiled plumage and a dark, encrusted lesion on its back and wing.

Exhibit B, Photograph 5



Turkey in the flock standing with one leg splayed to the side.

EXHIBIT C

Veterinary Records of the Five Turkeys Removed from the Farm (Redacted), October 9–21, 2026

[redacted]

Visit Summary

Visit Date: October 09, 2026 01:17 PM

[redacted]

Turkey 3 ([redacted])
D.O.B.: 07/09/2026 | 6.6kg | 0y 3m | Bird | Other Bird | MI
Patient ID: [redacted]

Status: Outpatient

CUSTOMER

[redacted]

PRIMARY RDVM

[redacted]
Office: [redacted]

PRESENTING COMPLAINTS

HISTORY

This is an \~3-month old MI turkey presenting in a group of five total turkeys. These turkeys were obtained from a local farm earlier today by a rescue. The turkeys are lethargic, caked in feces, limping, and have wounds. They have not received any treatments so far. There is no reported significant medical history.

VITALS

SYSTEM	INTAKE
Mentation	QAR
Heart Rate	200 BPM
Weight	6.6 KG

PROBLEMS AND DIFFERENTIALS

PROBLEMS	DIFFERENTIALS

NOTES

October 09, 2026 at 01:58 PM

Progress Note

Blue band
Weight: 6.6kg
BCS: 2/5
Hydration: \~5% dehydrated
EENT: Anterior chambers clear OU. No oculonasal discharge. Crop palpates normally.
Oral: No plaques or foreign material present.
Respiratory: Eupneic. No abnormalities on auscultation of air sacs.
Cardiovascular: Heart arrhythmia noted on auscultation. No overt murmur.
Coelom: No overt abnormalities on palpation.
Integument: Mild bruising of right medial elbow. No crepitus or other abnormalities noted of right elbow on manipulation. Multiple broken feathers.
Musculoskeletal: Swollen right intertarsal joint. Crepitus on palpation of right intertarsal joint. Bruising just proximal/ caudal to right intertarsal joint.
Nervous system: BAR. No overt neurologic deficits noted.
Cloaca: Moderate fecal staining. Diarrhea with hematochezia present in crate.

PROBLEM LIST/DIFFERENTIALS

-Swollen right intertarsal joint with crepitus on manipulation, r/o infectious vs. nutritional vs. traumatic vs. other
-Bruising proximal/caudal to right intertarsal joint
-Bruising of right medial elbow
-\~5% dehydrated
-Diarrhea with hematochezia, r/o coccidia vs. other parasitic vs. less likely viral vs. less likely bacterial
-Moderate fecal staining of feathers
-Heart arrhythmia on auscultation, r/o normal variant vs. cardiac vs. other

RECOMMENDATIONS/CLIENT COMMMUNICATION

Requested permission to temporarily tag the turkeys with colored plastic ties around their legs to differentiate them. Owners approved.

Discussed hemorrhagic diarrhea found in the majority of the kennels containing the turkeys and concern for coccidia. Recommended TMS to go home which would address potential coccidia. Offered a five day course of this antibiotic, but discussed that this may need to be continued longer than five days. Recommended a recheck with an avian veterinarian early this week (in 3-5 days maximum) to discuss longer treatment of suspected coccidia.

Also discussed finding of this turkey having a heart arrhythmia on auscultation today which could be incidental, but we cannot rule out underlying heart disease. Recommended further evaluation with an avian or exotics veterinarian.

Discussed mild dehydration of majority of turkeys on examination. Recommended subcutaneous fluid administration.

After examining all five turkeys, discussed concern for multiple orthopedic abnormalities and swollen joints. Discussed concern for septic joints of some of these turkeys. Recommended starting doxycycline to address this (discussed that oxytetracycline would be better, but we are unable to source this medication at this time.) Offered to obtain conjunctival, choanal, and cloacal swabs to consider submission with pDVM to test for infectious causes of these swollen joints such as for mycoplasma. Did not charge to obtain the samples, but discussed that an additional charge may be required for submission of testing of these swabs. Discussed that if starting doxycycline, these turkeys could not be consumed by humans in the future and verbally confirmed with the rescue that they would not be used for meat consumption at any point in the future. Also offered meloxicam for pain.

Discussed concern for these turkeys having underlying infectious illness such as coccidia +/- mycoplasma. Recommended strict quarantine of these turkeys away from other birds in their facility until otherwise directed.

Discussed potential longterm requirements and concerns for these turkeys. Discussed that these turkeys are juvenile meat turkeys who are likely to put on significant additional weight as they grow. Discussed concern for multiple orthopedic abnormalities in many turkeys which may become a quality of life concern in the future, especially with additional body weight. Discussed that these turkeys are prone to diseases such as pododermatitis and cardiac disease in the best scenarios. Discussed likelihood that many of these turkeys would likely require further extensive treatment of their wounds/joints and emphasized the potential financial commitment they may require.

After speaking with [redacted] relayed that [redacted] may or may not be able to see the turkeys in the future due to strict criteria of any avian patients they are seeing due to HPAI. Discussed recommendations of [redacted] to consider TMS, meloxicam, and doxycycline to go home to get these turkeys started on treatment. Discussed further treatment may include wound debridements, limb perfusions, etc. Recommended prompt re-evaluation by an avian veterinarian early this week for more updated recommendations. Sent owners with a list of local exotics veterinarians in the area. Owners were understanding and approved the above recommendations. Discussed clinical signs to monitor for and recommended notifying us if concerns arise.

DIAGNOSTICS
-None submitted at time of visit
-CTAs in a sterile white top tube obtained of each turkey from conjunctiva, choana, and cloaca (one swab total per turkey collected in that order) which was placed in the fridge to consider submission with an avian veterinarian early this week.

PLAN TREATMENTS
-LRS 150mL SC

Prognosis: Guarded
RX:
-Meloxicam \~1mg/kg PO SID-BID x 7d
-TMS 30mg/kg PO BID x 5d
-Doxycycline \~5mg/kg PO SID x 7d
-Dilute chlorhexidine applied to external wounds BID x 7d
-Follow up with an avian veterinarian in 3-5 days

[redacted] DVM

October 12, 2026 at 06:04 PM
Progress Note

October 12, 2026 at 06:04 PM
Progress Note

October 12, 2026 at 06:05 PM
Progress Note

October 12, 2026 at 06:07 PM
Progress Note

TREATMENT SUMMARY

[redacted]

Treatment Sheet

[redacted]

Turkey 3 ([redacted]) | [redacted] | 0y 3m, MI, Bird

Friday, Oct 9, 2026 (Day 1 of 1)

ORDER	12AM	1AM	2AM	3AM	4AM	5AM	6AM	7AM	8AM	9AM	10AM	11AM	12PM	1PM	2PM	3PM	4PM	5PM	6PM	7PM	8PM	9PM	10PM	11PM
VITALS																								
Weight															6.6 kg									
Heart Rate															200 BPM									
Check Mentation															QAR									
TASKS																								
Administer Subcutaneous / SQ Flu…																								

Notes IC Incomplete Complete **Treatment Details**: To view details, please visit [redacted]

[redacted]

Discharge Summary

Visit Date: October 09, 2026 01:17 PM

[redacted]

Turkey 3 ([redacted])
D.O.B.: 07/09/2026 | 6.6kg | 0y 3m | Bird | Other Bird | MI
Patient ID: [redacted]

Status: Outpatient

CUSTOMER	PRIMARY RDVM
[redacted]	[redacted] Office: [redacted]

MEDICATIONS

TMS (Sulfamethoxazole/Trimethoprim) 48 mg/mL Oral
Give 4.2mL by mouth every 12 hours for 5 days. This is an antibiotic and a treatment for coccidia.

Total Qty: 42.0 mL
Next Dose: This evening

Meat withdrawal times: 8 weeks Egg withdrawal times: 8 weeks

Meloxicam 7.5 mg Tablets
Give 1 tablet by mouth every 12-24 hours for pain. This is an anti-inflammatory.

Total Qty: 14.0 tablet
Next Dose: This evening

Egg withdrawal time: 8 days Meat withdrawal time: Indefinite

Doxycycline 100 mg Tablets
Give 1/2 tablet by mouth every 24 hours until gone. This is an antibiotic.

Total Qty: 4.0 tablet
Next Dose: This evening

Egg withdrawal time: Indefinite Meat withdrawal time: Indefinite

HOME CARE AND MONITORING

These turkeys presented to [redacted] after being rescued from a farm with wounds and lameness. Multiple turkeys were found to have external/scabbed wounds as well as diarrhea with blood. We are sending home an antibiotic by mouth (TMS) to help prevent infection of the wounds and to treat potential coccidia (a gastrointestinal parasite.) Multiple turkeys also had swollen joints which are concerning for infection or nutritional deficiency, but we cannot rule out trauma. We are sending home another antibiotic (doxycycline) in case of infectious joints. Due to this, you may never consume the turkeys for meat. We administered fluids underneath the skin of these turkeys to help with hydration. We are also sending an antimicrobial solution (chlorhexidine) to be applied to the outside of the wounds twice daily and a pain medication (meloxicam.)

MEDICATIONS
Name: TMS
Description: This is an antibiotic.
Missed Dose: Give it when you remember. If the next dose is less than 6 hours from when you give it, skip that dose and give it at the appropriate time after.

Storage: Room temperature if tablet, refrigerator if liquid
Adverse Effects: Vomiting, diarrhea, decreased appetite, Increased thirst and urination, dry eye
Additional Warnings: This medication is not recommended in patients that have severe liver or blood problems or are dehydrated. Caution should be used in Doberman dogs, animals with kidney or bladder stone history, or older animals.

Name: Doxycycline
Description: This medication is an antibiotic.
Storage: Room temperature, protected from light and heat. Oral suspension, once mixed, should be store at room temperature and is stable for 14 days after mixing. Throw out any remaining suspension after 14 days.
Adverse Effects: Vomiting, stomach upset, decreased appetite, diarrhea, regurgitation, trouble swallowing, decreased energy levels, fever, bloody vomit, bloody stool, yellow skin/eyes/gums, painful abdomen, bleeding, seizures, changes in behavior.
Additional Warnings: Do not give as a dry pill or capsule. Give with a treat or small amount of liquid. Can cause ulcers in the throat and esophagus if gets stuck before reaching stomach. May upset stomach, give with a small amount of food. Do not give multivitamins, antacids, laxatives or calcium supplements within 2 hours before or after giving doxycycline as it may decrease its efficacy.

Name: Meloxicam
Description: This medication is a non-steroidal anti-inflammatory pain medication.
Storage: Room temperature, protected from light
Adverse Effects: Vomiting, Diarrhea, Decreased appetite. Dark stool, central nervous system signs, gum color changes and skin redness are less effects.
Additional Warnings: This medication should not be added to a pet who is on other NSAIDs or steroids. This medication should be used with caution in cats. Caution should be used in patients who have stomach ulcers, are dehydrated, or have liver/kidney problems. Caution should also be used in young patients (under 6 months)

MONITORING
Please monitor for regurgitation, lethargy, pain, inappetence, difficulty breathing, etc. and notify us if concerns arise.

Please also monitor the wounds for redness, swelling, or discharge, and notify us if concerns arise.

RECHECK
We recommend following up with an exotics or avian veterinarian for further treatment of these turkeys as soon as possible (within 3-5 days.) We have attached a list of local exotics veterinarians in the area below.

The following is a list of general practice exotics veterinarians in the area which may be able to help you :
[redacted]-[redacted]
[redacted]-[redacted]

Thank for you trusting [redacted] with the care of your pet! We will send your pet's medical records to their primary care veterinarians office, so they are updated on today's visit! It was a pleasure meeting you! Please let us know if you have any questions or concerns.

We strive to provide the highest quality veterinary care for our community!

[redacted] DVM




So You Want to Be a Veterinarian?





Exhibit C, Intake Photograph 1



Wound photographed at veterinary intake, October 9, 2026.

Exhibit C, Intake Photograph 2



Wound photographed at veterinary intake, October 9, 2026 (close view).

Pet Health Report Card

Client ID: [redacted]
[redacted], [redacted]
[redacted]

Patient ID: [redacted]
Patient Name: Yellow
Species: Avian Breed: Turkey
Weight: 17.6 pounds
[redacted] [redacted] Birthday: 7/12/2026 Sex: Unknown

Staff: [redacted] Technician: [redacted] Exam Date: 10/14/2026

PRESENTING COMPLAINT - HISTORY: (ABNORMAL)
A young turkey labeled "Yellow" is presented to establish care and to assess some concerns. Yellow was aquired along with two other turkeys from a factory farm on Saturday. They have been checked out by [redacted] in [redacted] and there are infectious swab results still pending. All three turkeys are currently being treated with SMZ, doxycycline, and meloxicam for significant bilateral wounds to their body for the last 5 days. Yellow is also having a very difficult time wallking and is described as bow legged. E/D slightly less than the other two turkeys. Makes a gurgling sound when receiving medications but no other respiratory signs. Is having diarrhea that started out looking bloody and some small worms were thought to be seen in a few samples. Currently getting Corid.

Appearance, Weight, Temperature: (Normal)
17.6#, BCS: good

Diet/Husbandry: (Normal)
New to sanctuary w/ two other turkeys - are currently in quarantine

Vaccines: (Did Not Examine)

Mentation: (Normal)
BAR

Eyes: (Normal)

Ears: (Normal)

Oral Cavity: (Normal)
Normal rhinotheca/gnathotheca

Abdomen and Abdominal Organs: (Normal)
soft, not distended

Rectum & Anal Glands: (Normal)

Respiratory: (Normal)
Eupnic during exam

Cardiovascular: (Normal)
No murmur/arrhythmia

Lymph Nodes: (Did Not Examine)

Urogenital: (Did Not Examine)

Nervous System: (Normal)
No ataxia, no star gazing/wry neck, no head tilting, no rolling

MUSCULOSKELETAL: (ABNORMAL)
Bilateral varus deformity of legs, no obvious swelling, no fractures of osteomyelitis of the bones.

INTEGUMENT: (ABNORMAL)
L sided wound is severe w/ major anterior/cranial pocketing down lateral aspect of the leg. Two smaller caudal superficial wounds on the L side, one smaller superficial scabbed wound on the R side.

Age-Specific Concerns: (Normal)

Infectious Diseases: (Normal)
N/A

DIAGNOSIS: (ABNORMAL)
Varus Deformity - r/o ligament laxity as primary cause vs abnormal bone growth vs both. Infected wounds w/ pocketing.
Diarrhea - r/o parasitic vs other

Pet Health Report Card

Client ID: [redacted]
[redacted]
[redacted]
[redacted]

Patient ID: [redacted]
Patient Name: Yellow
Species: Avian Breed: Turkey
Weight: 17.6 pounds
Birthday: 7/12/2026 Sex: Unknown

Staff: [redacted] Technician: [redacted] Exam Date: 10/14/2026

Client Communication: (Normal)

Discussed QoL in this turkey due to current bilateral leg varus deformity. Yellow needs surgical intervention for pocketing wound on the L side of the body, however, discussed if sanctuary wants to put this bird through surgery when her long term prognosis is guarded due to her mobility issues. Surgery involves anesthesia and carries risk since this bird is not healthy to start. Long term mobility concerns center around a growing bird that as a result of the deformity will likely develop significant osteoarthritis and is more susceptible to bumblefoot as time goes on. Sanctuary feels a wheelchair may be a good option for Yellow as they have had birds do well with these in the past. May need long term pain managment. Is interested in debridement surgery and will possibly schedule for Tues 10/20.

Comments/Treatments: (Normal)

Radiographs, pooled fecal sample (Red + Yellow) - pending

If you have any questions about your pet's physical exam, please call our office.

Pet Health Report Card

Client ID: [redacted]
[redacted]
[redacted]
[redacted]

Patient ID: [redacted]
Patient Name: Red
Species: Avian Breed: Turkey
Weight: 16.7 pounds
Birthday: 7/12/2026 Sex: Unknown

Staff: [redacted] Technician: [redacted] Exam Date: 10/14/2026

PRESENTING COMPLAINT - HISTORY: (ABNORMAL)
A young turkey labeled "Red" is presented to establish care and to assess some concerns. Red was aquired along with two other turkeys from a factory farm on Saturday. They have been checked out by [redacted] in [redacted] and there are infectious swab results still pending. All three turkeys are currently being treated with SMZ, doxycycline, and meloxicam for significant bilateral wounds to their body for about 5 days. Red is also limping on the left leg as well. E/D normal, no respiratory signs. Is having diarrhea that started out looking bloody and some small worms were thought to be seen in a few samples. Currently getting Corid.

Appearance, Weight, Temperature: (Normal)
16.7#, BCS: good

Diet/Husbandry: (Normal)
New to sanctuary with two other turkeys - are currently in quarantine

Vaccines: (Did Not Examine)

Mentation: (Normal)
BAR

Eyes: (Normal)

Ears: (Normal)

Oral Cavity: (Normal)
normal rhinotheca/gnathotheca

Abdomen and Abdominal Organs: (Normal)
soft, not distended, proventriculus is prominent on rads

Rectum & Anal Glands: (Normal)
Cloaca not prolapsed. There is fecal staining.

Respiratory: (Normal)
Eupnic

Cardiovascular: (Normal)
No murmur/arrhythmia

Lymph Nodes: (Did Not Examine)

Urogenital: (Did Not Examine)

Nervous System: (Normal)
No ataxia, no rolling, no head tilting

MUSCULOSKELETAL: (ABNORMAL)
L weight bearing lameness: L leg is edematous w/ a grape sized SQ nodule at the medial aspect. FNA of this swelling reveals clear/yellow tinged fluid. Rads did not reveal any fractures or osteomyelitis of the legs.

INTEGUMENT: (ABNORMAL)
Bilateral scabbed wounds on the body with the L sided wound being larger and more severe than the right. No obvious pocketing of these wounds noted.

Age-Specific Concerns: (Normal)

Infectious Diseases: (Normal)
N/A

DIAGNOSIS: (ABNORMAL)
L leg soft tissue swelling - r/o lymphatic drainage vs infection vs inflammatory vs other. Intermittent diarrhea - r/o parasitic causes vs other. Infected skin wounds.

Client Communication: (Normal)
Recommended continuation of current medications. Requested records from [redacted] Discussed continuation of chlorhex spray and applying SSD cream topically to the wounds. Recommended cold compress of the swollen leg w/ lymphatic massage toward the body if Red will tolerate. Pooled fecal sample submitted for Red and Yellow today. Will reach out w/ results and probable deworming treatments.

If you have any questions about your pet's physical exam, please call our office.

Pet Health Report Card

Client ID: [redacted]
[redacted]
[redacted]
[redacted]

Patient ID: [redacted]
Patient Name: Red
Species: Avian
Breed: Turkey
Weight: 16.7 pounds
Birthday: 7/12/2026
Sex: Unknown

Staff: [redacted]
Technician: [redacted]
Exam Date: 10/14/2026

Comments/Treatments: (Normal)

SSD cream script, radiographs, pooled fecal sample (Red + Yellow) - pending

If you have any questions about your pet's physical exam, please call our office.

Pet Health Report Card

Client ID: [redacted]
[redacted]
[redacted]
[redacted]

Patient ID: [redacted]
Patient Name: Green
Species: Avian Breed: Turkey
Weight: 15.3 pounds
Birthday: 7/12/2026 Sex: Female

Staff: [redacted] Technician: [redacted] Exam Date: 10/15/2026

Presenting Complaint - History: (Normal)
P is presented today for wounds and having some softer stools that are now improving. O currently has P on meloxicam, Doxycycline, SMZ TMP and corid. O has been using vetoryl spray on P's wounds. O just wanted to have P looked at since P just came into their care from a factory farm. Patient has a left leg lameness and swelling of the area. Patient is still acting normally and taking medication well. Patient had an excede injection and is finsihing the course of SMZ and doxycycline today.

Appearance, Weight, Temperature: (Normal)
BAR, BCS 5/9

Diet/Husbandry: (Normal)

Vaccines: (Normal)

Mentation: (Normal)
WNL

Eyes: (Normal)
WNL

Ears: (Did Not Examine)

ORAL CAVITY: (ABNORMAL)
MM pink, tip of rhinotheca broken

Abdomen and Abdominal Organs: (Normal)
No abnormalities noted on palpation

Rectum & Anal Glands: (Normal)
WNL

Respiratory: (Normal)
Bronchovesicular sounds WNL

Cardiovascular: (Normal)
No murmur or arrhythmia noted

Lymph Nodes: (Normal)
No lymphadenopathy noted

Urogenital: (Normal)
WNL

Nervous System: (Normal)
No head tilt noted

MUSCULOSKELETAL: (ABNORMAL)
L leg swollen from the tarsus and distally, fluctuant swelling of the medial L tarsus with yellow tinged fluid aspirated from the area, L leg weight bearing lameness

INTEGUMENT: (ABNORMAL)
Scabbed wound of the L patagium

Age-Specific Concerns: (Normal)

Infectious Diseases: (Normal)
N/A

DIAGNOSIS: (ABNORMAL)
L leg swelling- diagnosis open, r/o infection vs inflammation vs lymphatic vs other

Client Communication: (Normal)
On PE, a scabbed wound of the patagium noted. Recommended we treat with continued antibiotic therapy as well as cleaning and topical SSD application. Patient's L leg is quite swollen with fluid filled areas around the medial stifle. Recommended radiographs to look for boney involvement. Radiographs look pretty good; there is a questionable area that we can monitor with recheck radiographs if patient isn't improving. Recommended treating with continued antibiotics and anti-inflammatory medications as well as massaging the leg upwards in case the swelling is a lymphatic draiinage issue.

If you have any questions about your pet's physical exam, please call our office.

Pet Health Report Card

Client ID: [redacted]
[redacted]
[redacted]

Patient ID: [redacted]
Patient Name: Green
Species: Avian
Breed: Turkey
Weight: 15.3 pounds
[redacted]
Birthday: 7/12/2026
Sex: Female

Staff: [redacted]
Technician: [redacted]
Exam Date: 10/15/2026

Comments/Treatments: (Normal)

If you have any questions about your pet's physical exam, please call our office.

[redacted]

Medrec #	[redacted]	Owner	[redacted]	Primary DVM	[redacted]
Patient	Franklin	[redacted]	[redacted]	Phone	
Sex	Unknown	Address	[redacted]	Fax	
Species	Avian		[redacted]	Email	
Breed	Turkey	Home Phone	[redacted]		
Color	White	Work Phone	( ) -		
DOB	6/1/2026	Cell Phone	[redacted]		
Weight (kg)	7.10 Weight (kg)	Email	[redacted]		

Discharge Report

Service: [redacted]
Date: 10/21/2026
Clinician(s): [redacted]
Student(s): [redacted]

Current Medications

Meloxicam (7.5mg/kg tablets): Give 1 tablet by mouth every 12 hours for discomfort. This is an anti-inflammatory and pain medication. Reach out to a veterinarian and consider discontinuing this medication if Franklin has significant diarrhea, bloody stool, inappetence, or lethargy.
Next dose due: tonight 10/21/26

Tramadol (50mg tablets): Give 2 tablets by mouth every 24 hours as needed for discomfort. **Doing can be increased to every 12 hours for significant pain**. This is an anti-inflammatory and pain medication. Side effects include sedation/sleepiness.
Next dose due: tonight 10/21/26

Franklin's TMS and doxycycline can be discontinued at this time

****DO NOT CONSUME MEAT OR EGGS WITHIN 21 DAYS OF ADMINISTERING EITHER OF THESE MEDICATIONS****

Current Problems/Diagnoses

1. Suspect slipped tendon of the right hock (tendon perosis)
    1. Severe deviation and swelling of the right intertarsal joint - suspect slipped tendon
2. Decreased range of motion of the end of the right wing (carpus) - suspect prior injury
3. Diffuse feather breakage

Plan

1. Thank you for bringing in Franklin! It's very kind of you to look out for these guys. As we discussed, we believe Franklin is a female at this time (though we cannot rule out the possibility of Franklin being a younger male)

2. Franklin presented for assessment of his right hock joint. On our physical exam we found that it was quite swollen, painful, and deviated at an abnormal angle. X-rays and feeling the joint under sedation showed that it is a slipped tendon. This is a common abnormality in poultry, particularly if they grow at excessive rates or have nutritional imbalances. Today we took x-rays and thankfully, there does not appear to be evidence of infection or any fractures (broken bones) associated with the joint. We did not sample the joint or run bloodwork as we do not have overt concern for infection or general disease at this time, therefore the antibiotics can be discontinued.

   For slipped tendons, there are a variety of possible treatment options. The most definitive treatment option is surgery. This is ideally done in much younger birds of smaller species and has a high rate of failure and complications. The other possibility is trying to get a custom brace (orthotic) that could help keep Franklin's joint normally aligned. This will not fix the problem but has a chance of keeping Franklin more comfortable and improving her mobility. The final option is trying to keep Franklin comfortable, and considering humane euthanasia if his mobility or pain worsen. Unfortunately, Franklin's breed (Broad Breasted White) is very prone to musculoskeletal problems even in individuals without overt orthopedic diseases, given their excessive growth and weight Franklin's prognosis for long term comfort is low.

1. Diet: Feed a balanced turkey/game bird diet as the primary diet. Avoid diets formulated to promote rapid growth or production, including high-energy broiler diets and layer feeds. Maintaining Franklin at a lean body condition is particularly important to minimize additional stress on the affected leg and other joints. Fresh water should be available at all times. Greens and other appropriate treats may be offered in moderation, but a balanced game bird diet should make up the majority of the diet.

2. Allow normal, comfortable activity as tolerated, but do not force Franklin to exercise if she appears painful or reluctant to walk. Provide good footing and easy access to food and water to minimize unnecessary strain on the affected limb.

3. Sex: Based on Franklin's physical characteristics today, Franklin is suspected to be female. Franklin currently lacks the more prominent male characteristics seen in Eleanor, including the developing elongated snood, prominent red/blue coloration of the head and facial skin, and developing male-type feathering. Sex cannot be considered definitively confirmed based on external appearance alone at this age, but Franklin's current characteristics are more consistent with a female turkey.

4. Monitor Franklin closely for worsening lameness, decreased weight bearing, increasing joint swelling or heat, skin irritation or wounds over the affected leg, decreased activity, difficulty accessing food or water, decreased appetite, or evidence of pain. If a brace is used in the future, the skin and foot should also be monitored closely for pressure sores, swelling, or other complications.

5. Franklin's long-term prognosis for normal mobility is poor because the tendon is persistently displaced and she is already relatively mature. The primary goal moving forward is maintaining comfortable mobility and a good quality of life. If Franklin becomes persistently painful or is no longer able to move comfortably despite pain management and supportive care, humane euthanasia may need to be considered.

6. Thank you for bringing in Franklin and taking such good care of her!

Current Medications: TMS, doxycycline

Visit Summary

Diagnostic Tests/Results

1. Physical Examination
2. X-rays of the legs: moderate soft tissue swelling surrounding the right hock. No evidence of a tumor or infection was found. The left leg appeared normal. Based on the radiographs and physical examination, these changes are most consistent with a chronic/developmental orthopedic abnormality

Treatments:

1. No treatments in hospital

Follow-up examination/communication

☐ Please set up a follow-up appointment if Franklin's difficulty walking or pain progress at home.

Contact Us

If you have a local veterinarian who referred you to [redacted] we will send them a summary of this visit.

Please contact us through phone [redacted] or email at [redacted] for any updates, questions, or concerns.

DOCTOR'S NOTES ----------

Brief History

- **PRESENTING COMPLAINT:** Franklin is an unsexed 4-month-old turkey who presented to [redacted] for recheck of joint swelling/lameness and wounds following rescue from poor conditions approximately 10 days ago. Both have reportedly improved significantly since rescue, with good appetite and activity, although intermittent diarrhea and joint abnormalities persist.
- **CURRENT MEDICATIONS:** TMS; doxycycline (last dose given today); meloxicam 7.5 mg PO q24h. Wounds are gently cleaned with chlorhexidine.
- **MOST RECENT VISIT: 09OCT26 –** [redacted] Franklin presented at approximately 3 months old with four other juvenile turkeys shortly after rescue from a local farm. The group was reportedly lethargic, fecally soiled, lame, and had multiple wounds. Franklin weighed 6.6 kg, BCS 2/5, and was approximately 5% dehydrated. Examination showed joint swelling/crepitus, bruising, and broken/soiled feathers, with differentials for the orthopedic abnormalities including infectious/septic joint disease vs nutritional disease vs trauma. Diarrhea with hematochezia and fecal staining was also noted, with coccidiosis as a primary concern and other parasitic, viral, and bacterial causes considered. A cardiac arrhythmia without an overt murmur was auscultated, with normal variant vs underlying cardiac disease considered. Conjunctival, choanal, and cloacal swabs were collected and refrigerated for possible infectious-disease testing; no diagnostics were submitted at that visit. Franklin received 150 mL LRS SQ and was discharged

with TMS 30 mg/kg PO BID × 5 days, doxycycline ~5 mg/kg PO SID × 7 days, meloxicam ~1 mg/kg PO SID–BID × 7 days, and dilute chlorhexidine to external wounds BID × 7 days. Strict quarantine from other birds was recommended due to concern for coccidia ± Mycoplasma, with prompt avian/exotics recheck recommended.

- **HUSBANDRY:** Housed together in quarantine in an approximately 10 × 10 ft enclosed stall with shavings/hay bedding, windows, and a grow light; also provided supervised outdoor sunlight. Diet consists primarily of 14% protein turkey/game bird crumble with some wild bird seed. No current supplements. No direct contact with other animals.

Physical Examination

Subjective

Mentation: BAR; mentally appropriate, stressed/resistant with restraint.
Hydration:
BCS: 4/9 (mildly decreased pectoral muscling for breed/age)

Objective

WT: 7.45 kg
Heart Rate: 220bpm
Respiratory Rate: eupneic (panting in room due to stress)
Eyes: clear corneas/anterior chambers/lens OU, normal fundic exam OU, no infraorbital swelling
Nose: symmetrical nares, no nasal discharge,
Crop: empty/normal thickness (suspect due to not eating this AM w/ transport)
Ears: clear aural canals
Beak/Oral: rhinotheca/gnathotheca occlusion, normal saliva viscosity, sharp and numerous choanal papilla, glottis clear, no masses/ulcerations/plaques, no foreign material under tongue, mm pink. **Rhinotheca shortened previously consistent with debeaking.**
Cardiac: no murmur or arrhythmia
Lungs/ Air sacs: eupneic, normal air sac sounds
Coelom: appropriate doughy consistency for species, concave/flat/convex coelomic profile, no egg/masses/fluid distention palpated
Musculoskeletal: ambulatory but moderate right pelvic limb lameness, **marked right distal limb/joint swelling with soft, fluctuant periarticular swelling and severe varus deviation. No concerns of left pelvic limb. Right wing distal to carpus is stiff with decreased extension/ROM; no appreciable active swelling noted.**
Integument: **poor feather quality (soiling/loss of feathers on keep, tarnished tail/wing feathers).** No ectoparasites, uropygial gland symmetrical, no evidence of pododermatitis, flighted
Vent/Cloaca: clean/no prolapse/normal tone,
Urofeces: small amount of clear urine, white semi solid urates, **variable consistency green/orange feces.**
Neuro: mentally appropriate, no obvious CN or spinal nerve deficits

Diagnostics/Treatments Performed Today

Sedation:

- Midazolam 1mg/kg, dexmedetomidine 25mcg/kg IM in pectoral
- ketamine 4mg/kg IM in pectoral
- Too light with initial sedation (reactive), deep sedation with ketamine, adequate for exam and radiographs.

Reversal:

- Atipamazole0.25mg/kg) IM in pectoral muscles

Diagnostics:

- Physical examination
- radiographs
  - Right Tarsus:
    - 1. There is moderate circumferential soft tissue swelling surrounding the right tarsal region, most pronounced lateral to the distal tibiotarsus. No evidence of septic arthritis, fractures, or luxations
  - Left Tarsus:No concerns

Treatments: none performed

Plan:

- TGH: tramadol 13mg/kg PO q24hr; meloxicam 1mg/kg PO q12hr as needed for pain indefinitely
- Recommend housing recommendations
- Recommend trying to obtain a custom brace for the intertarsal joint
  - Can consider surgery but poor prognosis for success
  - Otherwise consider humane euthanasia if poor quality of life

[redacted]

Medrec #	[redacted]	Owner	[redacted]	Primary DVM	[redacted]
Patient	Eleanor	[redacted]	[redacted]	Phone	
Sex	Unknown	Address	[redacted]	Fax	
Species	Avian		[redacted]	Email	
Breed	Turkey	Home Phone	[redacted]		
Color	White	Work Phone	( ) -		
DOB	6/1/2026	Cell Phone	[redacted]		
Weight (kg)	10.35 Weight (kg)	Email	[redacted]		

Discharge Report

Service: [redacted]
Date: 10/21/2026
Clinician(s): [redacted]
Student(s): [redacted]

Current Medications:

1. **CONTINE meloxicam as previously prescribed.**

2. **You may discontinue TMS or continue for an additional week as previously prescribed.**

3. **DISCONTINUE doxycycline.**

Current Problems/Diagnoses

1. Mild swelling of the right tibiotarsal joint - suspect previously injury vs. joint inflammation from increased weight-bearing due to breed
2. Diffuse feather breakage

Plan

1. Eleanor presented for a recheck following rescue with concerns for previous wounds, feather damage, and joint swelling. On examination today, Eleanor was bright and ambulatory with good weight bearing. Mild swelling of the **right tibiotarsal (ankle) joint** was noted; however, Eleanor continues to use the limb well and her overall attitude and mobility have improved since rescue. As discussed, the mild right tibiotarsal joint swelling is currently considered more likely related to **previous injury and/or inflammation associated with increased loading on the joints** rather than an active infection. Poultry breeds that grow rapidly and reach a large body size can be predisposed to musculoskeletal and joint problems.

2. **Continue meloxicam as prescribed** for inflammation and discomfort. Doxycycline may be discontinued. TMS may also be discontinued at this time; however, if you would prefer to be more conservative, it is reasonable to **continue TMS for one additional week**.

3. Monitor the **right tibiotarsal joint** closely for increasing swelling, heat, redness, pain, decreased weight bearing, lameness, holding the limb up, reluctance to walk, decreased activity, or other changes in mobility. Please contact [redacted] if any of these changes are noted.

4. **Diet:** Continue feeding a balanced **turkey/game bird diet** as the primary diet. Avoid diets formulated for rapid growth or production, such as high-energy broiler diets or layer feeds. Maintaining Eleanor at a **lean body condition** is particularly important because excessive body weight places additional stress on the joints. Fresh water should be available at all times. Appropriate greens and other treats may be offered in moderation, but the balanced game bird diet should make up the majority of the diet.

5. Continue allowing **normal, comfortable exercise** as tolerated. Regular movement may help maintain muscle strength and joint function; however, Eleanor should not be forced to exercise if she appears uncomfortable or reluctant to walk.

6. **Sex:** Based on Eleanor's physical characteristics today, **Eleanor is suspected to be male**. Features supporting this include the developing/elongated **snood**, more prominent red-to-blue coloration of the head and facial skin, and developing male-type feathering. These characteristics generally become more apparent as turkeys mature.

7. Monitor Eleanor's **appetite, fecal quality, activity level, mobility, wounds/skin, and feather condition** at home. Please contact us if you notice decreased appetite, persistent or worsening diarrhea, new wounds, worsening feather loss, or any change in comfort or mobility.

8. Thank you for bringing in Eleanor and for giving him a chance

Current Medications: None

Visit Summary

Diagnostic Tests/Results

1. Physical Examination (see Doctor's Notes for more information)

Treatments:

1. None

Follow-up examination/communication

☐ Please set up an appointment at [redacted] for yearly wellness appointments or sooner if new concerns arise.

Contact Us

If you have a local veterinarian who referred you to [redacted] we will send them a summary of this visit.

Please contact us through phone [redacted] or email at [redacted] for any updates, questions, or concerns.

DOCTOR'S NOTES ----------

Brief History

- **PRESENTING COMPLAINT:** Eleanor, an unsexed 4 month old turkey, presented to [redacted] for recheck of joint swelling/lameness and wounds following rescue from poor conditions approximately 10 days ago. Both have reportedly improved significantly since rescue, with good appetite and activity, although intermittent diarrhea and joint abnormalities persist.
- **CURRENT MEDICATIONS:** TMS; doxycycline (last dose given today); meloxicam 7.5 mg PO q24h. Wounds are gently cleaned with chlorhexidine.
- **MOST RECENT VISIT: 09OCT26 –** [redacted] Eleanor presented at approximately 3 months old with four other juvenile turkeys shortly after rescue from a local farm. The group was reportedly lethargic, fecally soiled, lame, and had multiple wounds. Eleanor weighed 8.4 kg, BCS 3/5, and was approximately 5% dehydrated. Examination showed superficial wounds and moderate fecal staining. She had a normal gait without overt lameness or palpable joint abnormalities. Diarrhea with hematochezia within the group raised concern for coccidiosis, with other parasitic, viral, and bacterial causes considered. Eleanor received SC fluids and was discharged with TMS 30 mg/kg PO BID × 5 days, meloxicam ~1 mg/kg PO SID–BID × 7 days, and dilute chlorhexidine to external wounds. Strict quarantine from other birds was recommended due to concern for coccidia ± mycoplasma, with avian/exotics recheck recommended.
- **HUSBANDRY:** Housed together in quarantine in an approximately 10 × 10 ft enclosed stall with shavings/hay bedding, windows, and a grow light; also provided supervised outdoor sunlight. Diet consists primarily of 14% protein turkey/game bird crumble with some wild bird seed. No current supplements. No direct contact with other animals.

Physical Examination

Subjective

Mentation: BAR
Hydration: <5% dehydrated?
BCS: 5/9

Objective

WT: 10.35 kg
Heart Rate: not obtained
Respiratory Rate: not obtained
Eyes: clear corneas/anterior chambers/lens OU, normal fundic exam OU, no infraorbital swelling,
Nose: symmetrical nares, no nasal discharge,
Crop: empty/normal thickness
Ears: clear aural canals.
Beak/Oral: normal rhinotheca/gnathotheca occlusion, normal saliva viscosity, sharp and numerous choanal papilla, glottis clear, no masses/ulcerations/plaques, no foreign material under tongue, mm pink. **Beak appears shortened/previously debeaked.**
Cardiac: no murmur or arrhythmia
Lungs/ Air sacs: eupneic, normal air sac sounds
Coelom: appropriate doughy consistency for species, concave/flat/convex coelomic profile, no egg/masses/fluid distention palpated
Musculoskeletal: ambulatory, symmetrically muscled, no fractures/soft tissue swellings of extremities, normal ROM wings and legs. Bilateral pelvic limbs symmetrical with normal ROM and weight bearing; no appreciable heat, or crepitus. **Mild swelling**

of the right distal tarsometatarsus at the metatarsophalangeal joints (mildly painful). Subtle lameness of right pelvic limb. Plantar surfaces without erythema, scabbing, or bumble formation.
Integument: **Diffuse feather breakage,** no ectoparasites, uropygial gland symmetrical, no evidence of pododermatitis, flighted **Small dry scab/wound near the left shoulder.** No significant wounds or keel lesions appreciated.
Vent/Cloaca: clean/no prolapse/normal tone, digital cloacal palpation no masses or blood noted.
Urofeces: small amount of clear urine, white semi solid urates, semi formed green feces.
Neuro: mentally appropriate, no obvious CN or spinal nerve deficits

Diagnostics/Treatments Performed Today
Sedation:

- None

Diagnostics:

- Physical examination

Treatments:

- None

EXHIBIT D

Jennie-O Turkey Store Veterinary Drug Prescriptions for the Litchfield Farm, 2021–2022

Exhibit D, Prescription 1

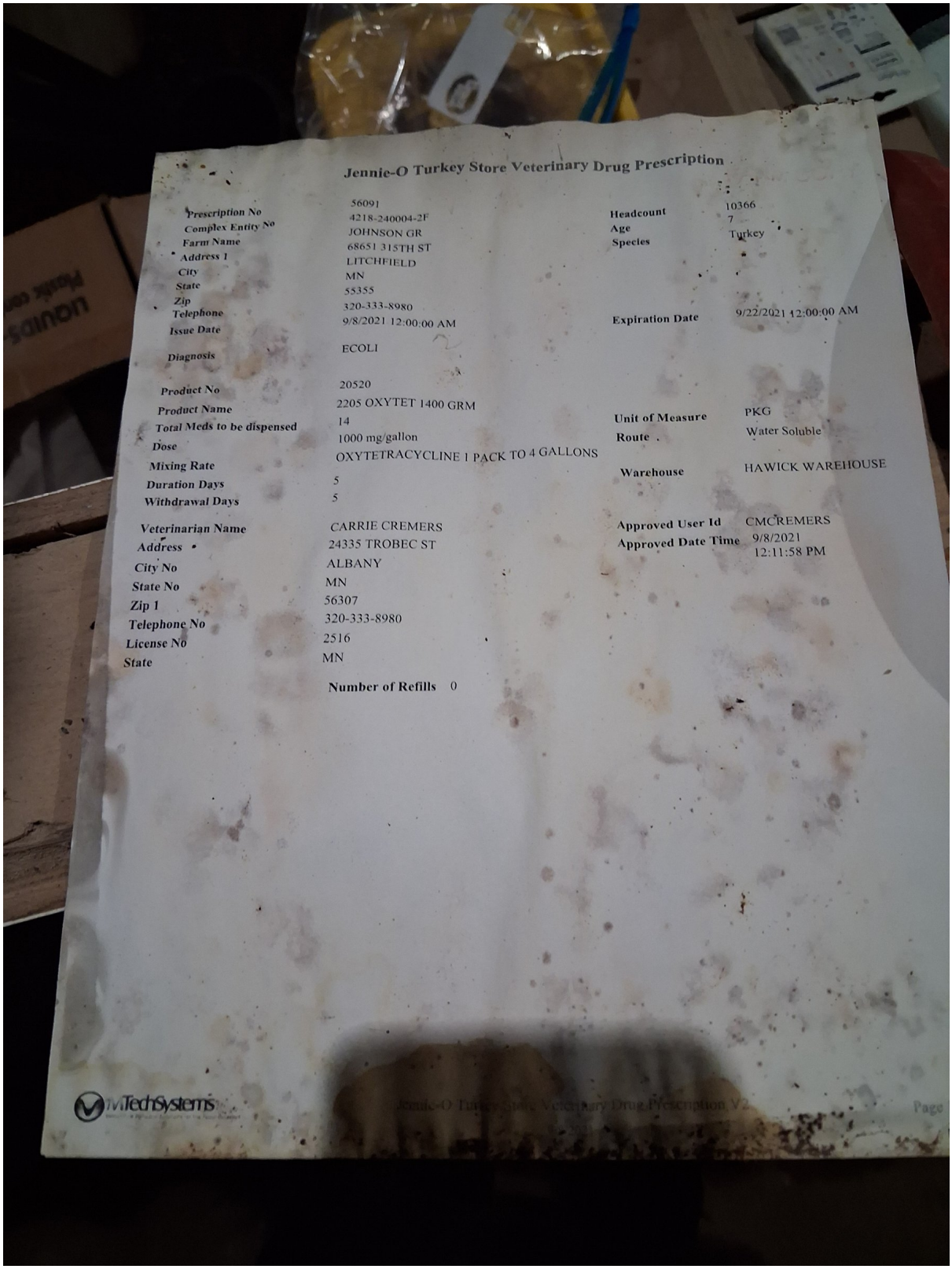

Jennie-O Turkey Store Veterinary Drug Prescription

Prescription No	56091		
Complex Entity No	4218-240004-2F	Headcount	10366
Farm Name	JOHNSON GR	Age	7
Address 1	68651 315TH ST	Species	Turkey
City	LITCHFIELD		
State	MN		
Zip	55355		
Telephone	320-333-8980		
Issue Date	9/8/2021 12:00:00 AM	Expiration Date	9/22/2021 12:00:00 AM
Diagnosis	ECOLI		
Product No	20520		
Product Name	2205 OXYTET 1400 GRM		
Total Meds to be dispensed	14	Unit of Measure	PKG
Dose	1000 mg/gallon	Route	Water Soluble
Mixing Rate	OXYTETRACYCLINE 1 PACK TO 4 GALLONS		
Duration Days	5	Warehouse	HAWICK WAREHOUSE
Withdrawal Days	5		
Veterinarian Name	CARRIE CREMERS	Approved User Id	CMCREMERS
Address	24335 TROBEC ST	Approved Date Time	9/8/2021 12:11:58 PM
City No	ALBANY		
State No	MN		
Zip 1	56307		
Telephone No	320-333-8980		
License No	2516		
State	MN		

Number of Refills 0

MTechSystems

Jennie-O Turkey Store Veterinary Drug Prescription V2 Page

Prescription issued September 8, 2021 (oxytetracycline; diagnosis "ECOLI"). Photographed at the farm, October 9, 2026.

Exhibit D, Prescription 2

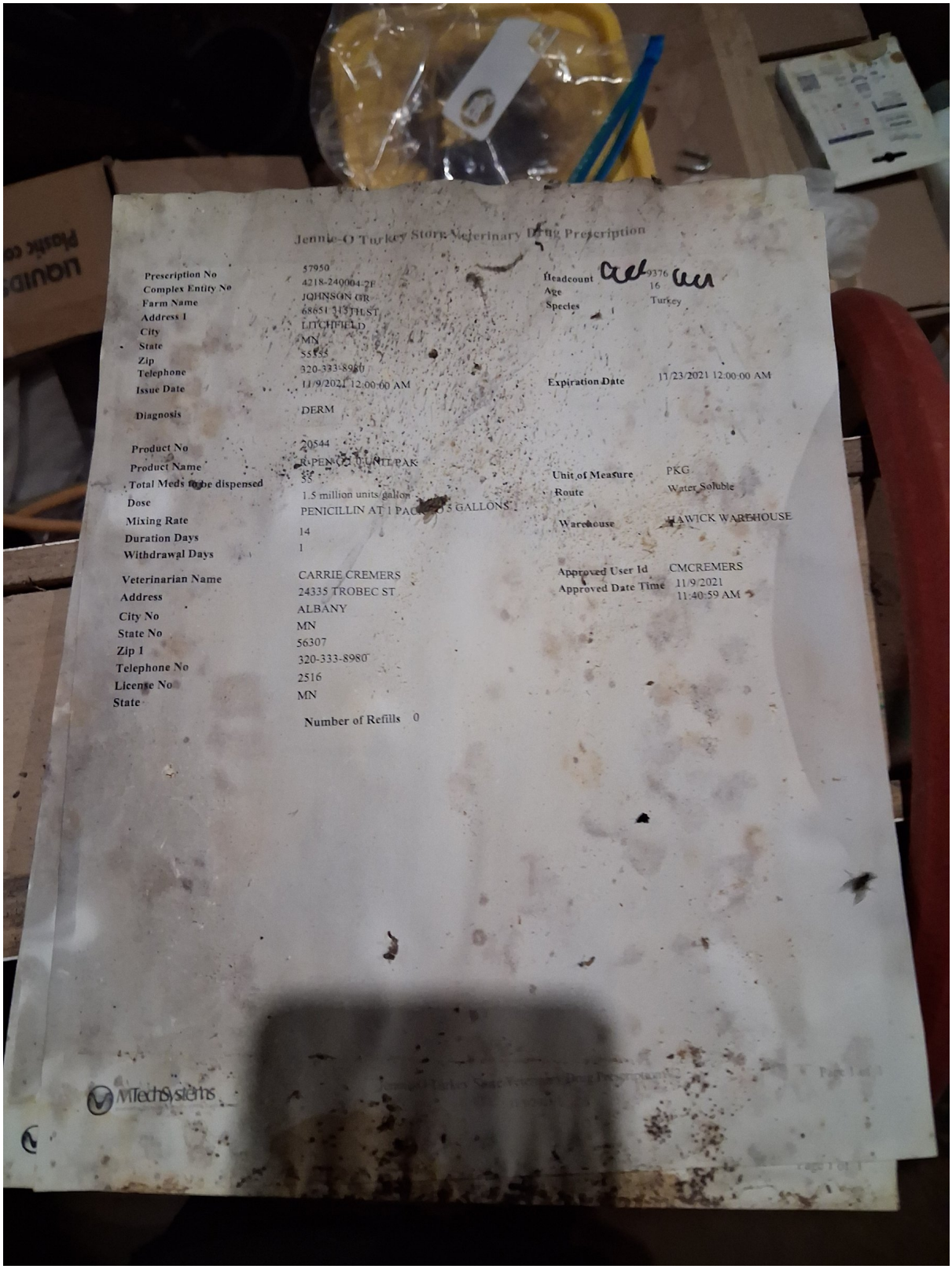

Jennie-O Turkey Store Veterinary Drug Prescription

Prescription No	57950
Complex Entity No	4218-240004-2F
Farm Name	JOHNSON GR
Address 1	68651 315TH ST
City	LITCHFIELD
State	MN
Zip	55355
Telephone	320-333-8980
Issue Date	11/9/2021 12:00:00 AM
Diagnosis	DERM
Product No	20544
Product Name	PENICILLIN G QUIL PAK
Total Meds to be dispensed	35
Dose	1.5 million units/gallon
Mixing Rate	PENICILLIN AT 1 PAC / 5 GALLONS
Duration Days	14
Withdrawal Days	1
Veterinarian Name	CARRIE CREMERS
Address	24335 TROBEC ST
City No	ALBANY
State No	MN
Zip 1	56307
Telephone No	320-333-8980
License No	2516
State	MN
Number of Refills	0

Headcount	9376
Age	16
Species	Turkey
Expiration Date	11/23/2021 12:00:00 AM
Unit of Measure	PKG
Route	Water Soluble
Warehouse	HAWICK WAREHOUSE
Approved User Id	CMCREMERS
Approved Date Time	11/9/2021 11:40:59 AM

MTechSystems

Prescription issued November 9, 2021 (penicillin G; diagnosis "DERM"). Photographed at the farm, October 9, 2026.

Exhibit D, Prescription 3

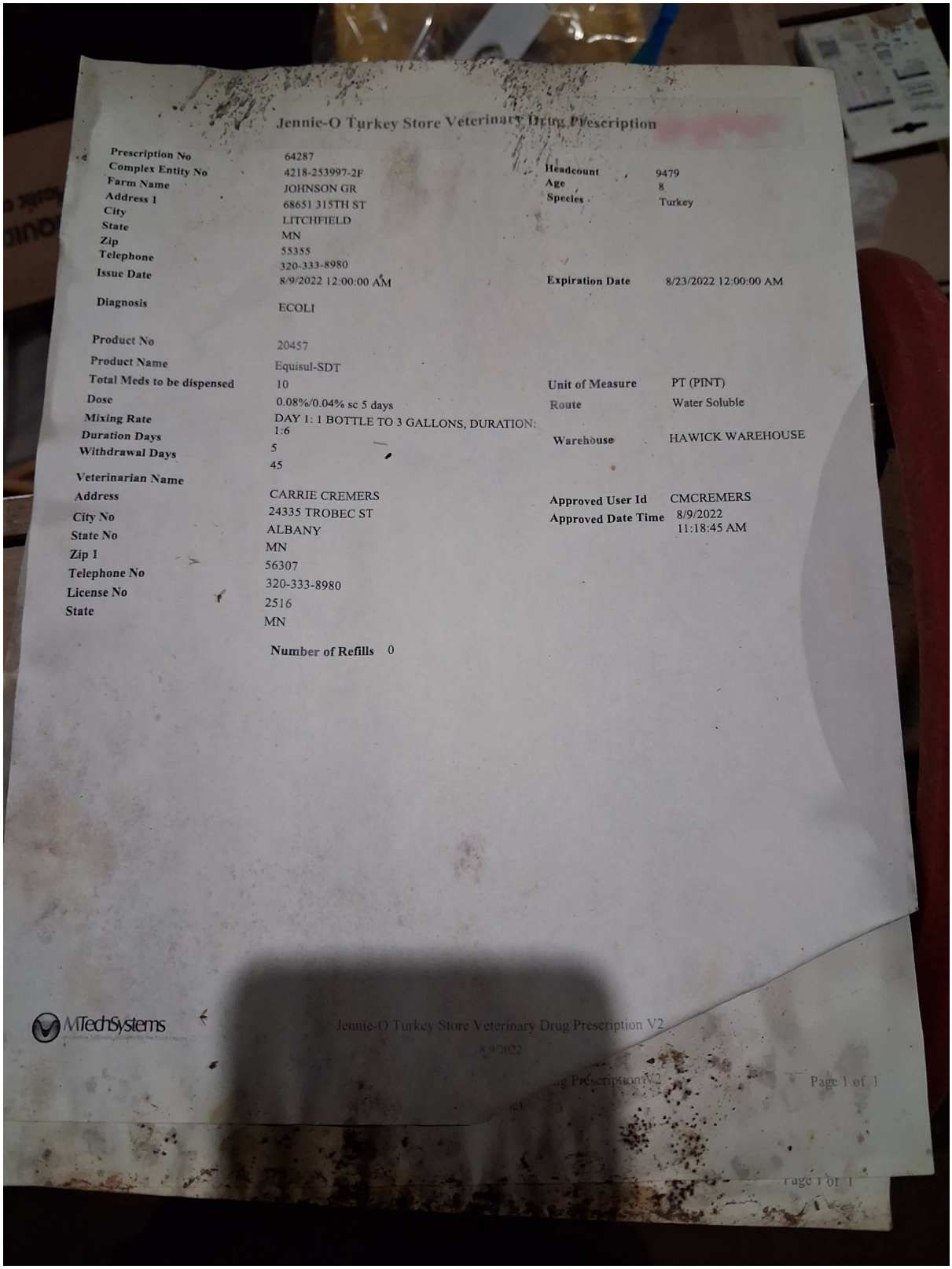

Jennie-O Turkey Store Veterinary Drug Prescription

Prescription No	64287		
Complex Entity No	4218-253997-2F	Headcount	9479
Farm Name	JOHNSON GR	Age	8
Address 1	68651 315TH ST	Species	Turkey
City	LITCHFIELD		
State	MN		
Zip	55355		
Telephone	320-333-8980		
Issue Date	8/9/2022 12:00:00 AM	Expiration Date	8/23/2022 12:00:00 AM
Diagnosis	ECOLI		
Product No	20457		
Product Name	Equisul-SDT		
Total Meds to be dispensed	10	Unit of Measure	PT (PINT)
Dose	0.08%/0.04% sc 5 days	Route	Water Soluble
Mixing Rate	DAY 1: 1 BOTTLE TO 3 GALLONS, DURATION: 1:6		
Duration Days	5	Warehouse	HAWICK WAREHOUSE
Withdrawal Days	45		
Veterinarian Name	CARRIE CREMERS		
Address	24335 TROBEC ST	Approved User Id	CMCREMERS
City No	ALBANY	Approved Date Time	8/9/2022 11:18:45 AM
State No	MN		
Zip 1	56307		
Telephone No	320-333-8980		
License No	2516		
State	MN		
Number of Refills	0		

MTechSystems

Jennie-O Turkey Store Veterinary Drug Prescription V2

8/9/2022

Page 1 of 1

Prescription issued August 9, 2022 (Equisul-SDT; diagnosis "ECOLI"). Photographed at the farm, October 9, 2026.

Exhibit D, Prescription 4

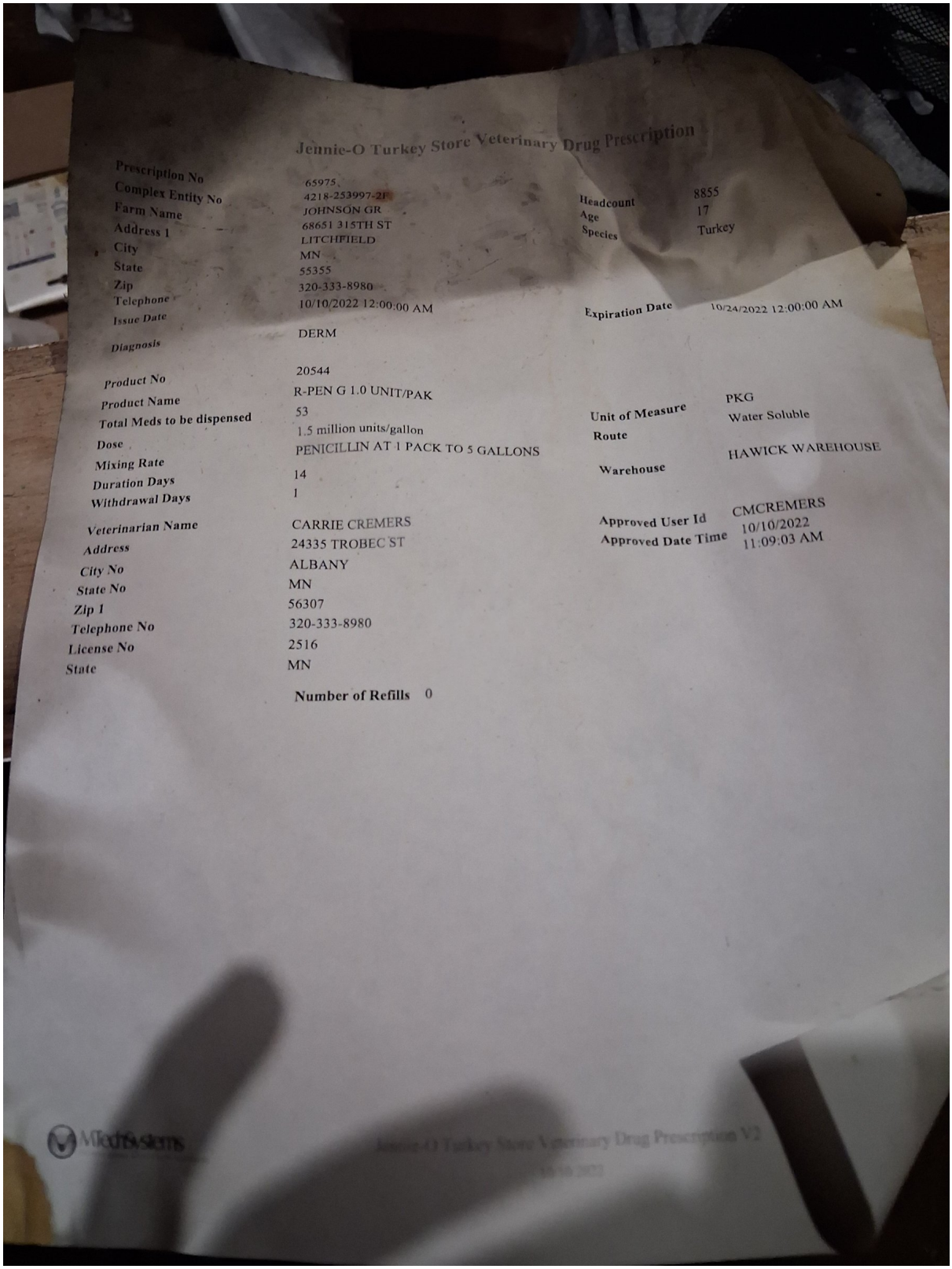

Jennie-O Turkey Store Veterinary Drug Prescription

Prescription No	65975		
Complex Entity No	4218-253997-2F	Headcount	8855
Farm Name	JOHNSON GR	Age	17
Address 1	68651 315TH ST	Species	Turkey
City	LITCHFIELD		
State	MN		
Zip	55355		
Telephone	320-333-8980		
Issue Date	10/10/2022 12:00:00 AM	Expiration Date	10/24/2022 12:00:00 AM
Diagnosis	DERM		
Product No	20544		
Product Name	R-PEN G 1.0 UNIT/PAK		
Total Meds to be dispensed	53	Unit of Measure	PKG
Dose	1.5 million units/gallon	Route	Water Soluble
Mixing Rate	PENICILLIN AT 1 PACK TO 5 GALLONS	Warehouse	HAWICK WAREHOUSE
Duration Days	14		
Withdrawal Days	1		
Veterinarian Name	CARRIE CREMERS	Approved User Id	CMCREMERS
Address	24335 TROBEC ST	Approved Date Time	10/10/2022 11:09:03 AM
City No	ALBANY		
State No	MN		
Zip 1	56307		
Telephone No	320-333-8980		
License No	2516		
State	MN		

Number of Refills 0

MedSystems

Jennie-O Turkey Store Veterinary Drug Prescription V2

Prescription issued October 10, 2022 (penicillin G; diagnosis "DERM"). Photographed at the farm, October 9, 2026.

EXHIBIT E

Order Denying Search Warrant Application, Meeker County District Court File No. 47-CV-25-274 (Mar. 28, 2025)

Filed in District Court
State of Minnesota
03/28/2025

STATE OF MINNESOTA
COUNTY OF MEEKER

DISTRICT COURT
EIGHTH JUDICIAL DISTRICT

Animal Partisan and
Animal Legal Defense Fund,

Complainants,

vs.

Jennie-O Turkey Store, Inc.,
Jennie-O Turkey Store International, Inc.,
and
Jennie-O Turkey Store, LLC,

Respondents.

Court File: 47-CV-25-274
Case Type: Civil

DENIAL OF SEARCH WARRANT

On March 28, 2025, this matter came before the Honorable Stephanie L. Beckman, Judge of District Court, on Complainants application for a search warrant pursuant to Minn. Stat. § 343.22 filed on March 20, 2025. This implicates Minnesota's Animal Cruelty statute

Complainants, Animal Partisan and Animal Legal Defense Fund (hereinafter "Complainants") are represented by Kira Kelley, Attorney-at-Law. Respondents, Jennie-O Turkey Store, Inc., Jennie-O Turkey Store International, Inc., and Jennie-O Turkey Store, LLC (collectively hereinafter "Respondents") are represented by Tyler Young, Attorney-at-Law.

FINDINGS OF FACT

1. On March 20, 2025, Complainants filed a search warrant application, and an affidavit from a veterinarian, alleging Respondents engaged in animal cruelty in an administrative search warrant pursuant to Minn. Stat. § 343.22 (Animal Cruelty statute).
2. On March 24, 2025, Respondents filed a Motion to Quash the warrant.
3. Complainants are nonprofit organizations located in Minnesota whose missions, in summary, are to protect animals.

4. Respondents are corporations registered with the Minnesota Secretary of State in St. Paul, MN but, have turkey barn business operations in Meeker County at 68651-315th Street, Litchfield and barns located in Willmar, Kandiyohi County, Minnesota.[1]

5. Complainants allege Respondent's violated Minnesota's Animal Cruelty statute, Minn. Stat. § 343.21, subd. 3, by failing to allow the turkeys enclosed in turkey barns to have a change of air when they euthanized them, which is a misdemeanor under this statute.

6. In Minnesota, a charge must be filed within three (3) years of an incident date from the offense. See, Minn. Stat. § 628.26(k).

7. Complainant argues that because Minnesota's law does expressly not allow for an agricultural exemption for farming practices, the act of sealing ventilation in a barn to prevent airflow to animals used in agricultural practices is punishable under the Animal Cruelty statute.

8. Complainants filed the application for a warrant and a request for the Court to order an investigation alleging the facts tend to establish grounds for a violation of the animal cruelty statute that has occurred or, is occurring, or probable cause to believe that a violation exists.

9. Complainants alleged a violation occurred when 50,000 birds, infected with avian influenza, were depopulated using VSD+, ventilation shutdown plus heat method, in October 2023. Complainants allege this method violates the Animal Cruelty statute to allow air flow and the Court should issue a search warrant. See, Minn. Stat. § 343.21, subd. 3.

[1] The application did not have the warrant with the requested relief and searches attached so the Court cannot be completely certain, but it appears Complainants are seeking the warrant and investigation solely for Meeker County and not the barns in Kandiyohi County.

10. After full review of the record submitted, this Court finds there is insufficient evidence of probable cause to believe a violation of Minn. Stat. § 343.21, subd. 3. Respondents were granted government authority (United States Department of Agriculture "USDA" and Minnesota Board of Animal Health "MBAH") for the depopulation of the animals, and the USDA and MBAH depopulation using foam and VSD+.

CONCLUSIONS OF LAW

Minnesota's Animal Cruelty Statute

1. Any person having reason to believe a violation of Minn. Stat. Ch. 343 has occurred or is occurring may apply to any court having jurisdiction over the allegations for a warrant and for an investigation. Minn. Stat. § 343.22, subd. 1.
2. The affidavits must set forth facts tending to establish grounds for believing a violation of this chapter has occurring or is occurring, or probable cause to believe that a violation exists. *Id.*
3. If a court is satisfied with the grounds in the application's existence or probable cause exists to believe the violation occurred, a warrant shall be issued and an investigation ordered for a peace officer in the county. *Id.*
4. Minnesota has very little caselaw associated with this statute.
5. A Brown County deputy searched a suspect's rural property after reports were received that she kept malnourished animals. The deputy was accompanied by a veterinarian and eleven (11) animals were seized finding them underweight and malnourished after a court issued a search warrant pursuant to Minn. Stat. § 343.22, subd. 1. *Lemarr v. Brown County,* 2021 WL 6010928, *3 (December 21, 2021, Minn. App.).

6. In *Lemarr v. Brown County,* the issue was whether Lemarr was under duress when she surrendered the animals, and the Court found the seizure of the animals did not occur in a coercive environment or under duress. *Id.* at *4.

7. The warrant appears to have been issued relatively close to when the allegations were made known to the county, but certainly not after months or years after. *Id.* at *3.

8. In *Compassion Over Killing, Inc. v. Quality Pork Processors, Inc.*, an animal rights group conducted an undercover investigation at a pork processing plant then told county officials and eventually applied for a search warrant. However, the court denied the warrant as stale having been 14 months old. 2017 WL4766999, *2-3 (October 23, 2017, Minn. App.).

Fourth Amendment- Search Warrants

9. "Under the fourth amendment, the probable cause to search cannot be established by stale information." *State v. Jannetta,*355 N.W.2d 189, 193 (Minn. App. 1984 (citing *United States v. Steeves,* 525 F.2d 33, 37-38 (8th Cir. 1975), *rev. denied* (Minn. Jan. 14, 1985)).

10. "Proof must be of facts so closely related to the time of the issuance of the warrants as to justify findings or probable cause at that time." *Id.* (*Sgro v. United States,* 287 U.S. 206, 210, 53 S. Ct. 138, 140 (1932)).

11. While there is no arbitrary or prescribed time limit to obtain a warrant, a practical common-sense question must be determined and used for each case, a court must find a reasonable time limit to the age of the evidence. *Compassion Over Killing, Inc. v. Quality Pork Processors, Inc.,* 2017 WL 4766999 at *3.

12. Warrants must be supported by probable cause under the United State and Minnesota constitutions. U.S. Const. Amend. IV; Minn. Const. Art. I, § 10; *State v. Bradford,* 618 N.W.2d 782 (Minn. 2000).

13. A court must determine whether there is a substantial basis to conclude whether probable cause existed based upon the totality of the circumstances there is "a fair probability that contraband or evidence of a crime will be found in particular place." *State v. Rochefort,* 631 N.W.2d 802, 804 (Minn. 2001).

14. The prior Minnesota case issued the warrant within a short period of time from the incidents alleged to assure incriminating evidence was obtained of the crimes alleged and to protect the animals who were allegedly maltreated. See. *Lemarr v. Brown County,* 2021 WL 6010928 at 3.

15. However, in *Compassion Over Killing, Inc. v. Quality Pork Processors, Inc.,* the Court denied the search warrant where it was 14 months later and there was no crime recently committed, unlikely evidence to be obtained, and no fair probability contraband or evidence of a crime was to be found. 2017 WL 4766999 at *3; *State v. Rochefort,* 631 N.W.2d at 804.

16. Here, Complainants seek a warrant seventeen (17) months after the incident. They allege that in October 2023 the animals were subjected to unlawful depopulation. However, the evidence establishes authorized depopulation was sanctioned by the USDA and MAHB because the animals were infected with avian influenza and Respondents justified the need for the use of foam and VSD+ as a method needed for animal disposal.

17. Further, even if a statutory violation occurred, evidence from the October 2023 incident is too remote or stale such that there is no incriminating evidence on the premises available any longer, and any animal bodies were extinguished per regulation given the extensive amount time that has elapsed, and there is no fair probability contraband or evidence of the crime would be available or found.

18. Last, there are no facts this Court finds sufficient to rely upon that establish incriminating evidence that a crime was committed or will be committed, or probable cause to believe a violation of the animal cruelty statute exists.

ORDER

1. Complainants' application for a search warrant pursuant to Minn. Stat. § 343.22, subd. 1 is hereby **DENIED.**
2. Complainants' application for an order of the court to order a county investigation and sheriff investigator to conduct an investigation pursuant to Minn. Stat. § 343.22, subd. 1 is hereby **DENIED.**

LET JUDGMENT BE ENTERED.

DATED: March 28, 2025

BY THE COURT:

Stephanie L. Beckman

Stephanie L. Beckman
JUDGE OF DISTRICT COURT

I certify the above order constitutes the Judgment of the Court.
Court Administrator

By:

03/28/2025 04:20 pm

MINNESOTA JUDICIAL BRANCH